

THE AAO  
**JOURNAL**



A Publication of the American Academy of Osteopathy

VOLUME 9 NUMBER 3 FALL 1999



**Osteopathic Manipulative  
Treatment and  
Meniere's Syndrome**

...see page 21

# AAO's CME Calendar

American Academy of Osteopathy®

3500 DePauw Boulevard, Suite 1080

Indianapolis, IN 46268-1136

Phone: (317) 879-1881 or FAX: (317)879-0563

## September

22-25 (Wed PM thru Sat AM)

*OMT Update*

Contemporary Hotel

Orlando, FL

Hours: 23 Category 1A

## October

1-3

*Stimulated Ligament Reconstruction  
(Prolotherapy)*

UNECOM

Biddeford, ME

Hours: 20 Category 1A

24-28

*AOA/AAO Convention*

Moscone Convention Center

San Francisco, CA

## November

12-14

*Introduction to OMT/Soft tissue/  
Articulatory Techniques*

COMP

Pomona, CA

Hours: 20 Category 1A

## December

10-12

*Visceral Manip. (Abdominal/GI)*

Holiday Inn Express

Phoenix, AZ

Hours: 24 Category 1A

## January, 2000

20-23

*Introduction to OMT/HVLA*

Sanibel Harbour Resort  
Florida

Hours: 23 Category 1A

## February

10-11

*Facilitated Positional Release*

Holiday Inn Airport

Indianapolis, IN

Hours: 12 Category 1A

11-13

*Myofascial Release*

Holiday Inn Airport

Indianapolis, IN

Hours: 20 Category 1A

## March

20-22

*Visceral Manipulation/Manual*

*Thermal Diagnosis*

Renaissance Cleveland Hotel

Cleveland, OH

Hours: 24 Category 1A

23-26

*2000 Annual Convocation*

*American Academy of Osteopathy*

Renaissance Cleveland Hotel

Cleveland, OH

Hours: 30+ Category 1A

## April

28-30

*Muscle Energy Tutorial*

Hilton Head, SC

Hours: 20 Category 1A

## May

12-14

*Stimulated Ligament Reconstruction/  
Above the Diaphragm (Prolotherapy)*

UNECOM

Biddeford, ME

Hours: 20 Category 1A

## June

14-16

*Dx and Tx of Low Back Pain*

Location TBD

Hours: 20 Category 1A

## July

14-16

*Alleviation of Common, Chronic Pain  
by Optimization of Posture*

OSUCOM

Tulsa, OK

Hours: 20 Category 1A

## August

17-20

*OMT Update*

Contemporary Hotel

Buena Vista, FL

Hours: 23 Category 1A

25-27

*Visceral Manipulation/Abdominal/GI*

Holiday Inn Airport

Indianapolis, IN

Hours: 24 Category 1A

## September

13-15

*Therapeutic Exercise with OMT*

Holiday Inn Airport

Indianapolis, IN

Hours: 20 Category 1A

16-17

*Advanced Percussion Vibrator*

Holiday Inn Airport

Indianapolis, IN

Hours: 14 Category 1A

## October

13-15

*Stimulated Ligament Reconstruction/  
Below the Diaphragm (Prolotherapy)*

UNECOM

Biddeford, ME

Hours: 20 Category 1A

October 29-November 2

*AOA/AAO Convention*

Orlando, FL

## December

1-3

*Visceral Manipulation/Thorax/Dura*

Holiday Inn Airport

Indianapolis, IN

Hours: 24 Category 1A



**1999-2000  
BOARD OF TRUSTEES**

President Mark S. Cantieri, DO, FAAO
President Elect John M. Jones, DO, III
Immediate Past President Melicien A. Tettambel, DO, FAAO
Secretary-Treasurer Anthony G. Chila, DO, FAAO
Trustee Stephen D. Blood, DO, FAAO
Trustee Boyd R. Buser, DO
Trustee Dennis J. Dowling, DO, FAAO
Trustee John C. Glover, DO
Trustee Ann L. Habenicht, DO, FAAO
Trustee Hollis H. King, DO, PhD, FAAO
Executive Director Stephen J. Noone, CAE

**Editorial Staff**

Editor-in-Chief .....	Raymond J. Hruby, DO, FAAO
Supervising Editor .....	Stephen J. Noone, CAE
Editorial Board .....	Barbara J. Briner, DO Anthony G. Chila, DO, FAAO James M. Norton, PhD Frank H. Willard, PhD
Managing Editor .....	Diana L. Finley

*The AAO Journal* is the official quarterly publication of the American Academy of Osteopathy, 3500 DePauw Blvd., Suite 1080, Indianapolis, Indiana, 46268-1136. Phone: 317-879-1881; FAX: (317) 879-0563; e-mail AAOSJN@aol.com; AAO Website: <http://www.aaomedguide.net>

Third-class postage paid at Carmel, IN. Postmaster: Send address changes to American Academy of Osteopathy 3500 DePauw Blvd., Suite 1080, Indianapolis, IN., 46268-1136

*The AAO Journal* is not itself responsible for statements made by any contributor. Although all advertising is expected to conform to ethical medical standards, acceptance does not imply endorsement by this journal.

Opinions expressed in *The AAO Journal* are those of authors or speakers and do not necessarily reflect viewpoints of the editors or official policy of the American Academy of Osteopathy or the institutions with which the authors are affiliated, unless specified.

**The mission of the American Academy of Osteopathy is to teach, advocate, advance, explore, and research the science and art of osteopathic medicine, emphasizing osteopathic principles, philosophy, palpatory diagnosis and osteopathic manipulative treatment in total health care.**

**Editorial Section**

From the Editor .....	5
<i>by Raymond J. Hruby, DO, FAAO</i>	
Message from the President .....	6
<i>by Mark S. Cantieri, DO, FAAO</i>	
Message from the Executive Director .....	7
<i>by Stephen J. Noone, CAE</i>	
Affiliated organization's CME Calendar .....	8
Five tips for year-end giving .....	9
From the AOBSPOMM Files: Case study: Osteopathic Manipulative Treatment of an 8-year-old child born with anoxia .....	10
<i>by Mary Anne Morelli, DO</i>	
Letter to A.T. Still .....	13
<i>by Raymond J. Hruby, DO, FAAO</i>	
Letters to the Editor .....	14
<i>David N. Grimshaw, DO; Robert Kidd, MD, CM; Richard C. MacDonald, DO; Dale E. Alsager, DO, PhD; John Rickelman, Jr., MS-IV, KCOM</i>	
Health services research: Evidenced-based medicine and the AAO five-year strategy .....	16
<i>by Albert F. Kelso, PhD and Deborah M. Heath, DO</i>	
From the Archives: <i>Philosophy of Osteopathy</i> , pages 260-262 .....	17
Student's Corner: case study: Low back pain in pregnancy .....	18
<i>by Kevin M. Gallagher, MS-III</i>	

**Peer-Reviewed Section**

Meniere's syndrome resulting from multiple traumatic brain injury: Two case studies .....	21
<i>by Wesley C. Lockhart, DO</i>	
Perspectives: An overview of support for osteopathy in the cranial field .....	25
<i>by Michael L. Kuchera, DO, FAAO</i>	
A review of the principles of William G. Sutherland's general techniques .....	32
<i>by William J. Golden, DO</i>	

**Advertising Rates for the AAO Journal**

*An Official Publication*

*of The American Academy of Osteopathy*  
The AOA and AOA affiliate organizations and members of the Academy are entitled to a 20% discount on advertising in this Journal.

Call: The American Academy of Osteopathy  
(317) 879-1881 for more information.

Subscriptions: \$60.00 per year (USA)  
\$68.00 per year (foreign)

**Advertising Rates:**

Full page \$600 placed (1) time	<i>Size of AD:</i> 7 1/2 x 9 1/2
\$575 placed (2) times	
\$550 placed (4) times	
1/2 page \$400 placed (1) time	7 1/2 x 4 3/4
\$375 placed (2) times	
\$350 placed (4) times	
1/3 page \$300 placed (1) time	2 1/4 x 4 3/4
\$275 placed (1) times	
\$250 placed (4) times	
1/4 page \$200 placed (1) time	3 1/3 x 4 3/4
\$180 placed (2) times	
\$150 placed (4) times	
Professional Card: \$60	3 1/2 x 2
Classified: \$1.00 per word (not counting a, an, the)	



# Instructions to Authors

The American Academy of Osteopathy (AAO) Journal is a peer-reviewed publication for disseminating information on the science and art of osteopathic manipulative medicine. It is directed toward osteopathic physicians, students, interns and residents and particularly toward those physicians with a special interest in osteopathic manipulative treatment.

The AAO Journal welcomes contributions in the following categories:

## **Original Contributions**

Clinical or applied research, or basic science research related to clinical practice.

## **Case Reports**

Unusual clinical presentations, newly recognized situations or rarely reported features.

## **Clinical Practice**

Articles about practical applications for general practitioners or specialists.

## **Special Communications**

Items related to the art of practice, such as poems, essays and stories.

## **Letters to the Editor**

Comments on articles published in *The AAO Journal* or new information on clinical topics. Letters must be signed by the author(s). No letters will be published anonymously, or under pseudonyms or pen names.

**Professional News** of promotions, awards, appointments and other similar professional activities.

## **Book Reviews**

Reviews of publications related to osteopathic manipulative medicine and to manipulative medicine in general.

## **Note**

*Contributions are accepted from members of the AOA, faculty members in osteopathic medical colleges, osteopathic residents and interns and students of osteopathic colleges. Contributions by others are accepted on an individual basis.*

## **Submission**

Submit all papers to Raymond J. Hruby, DO, FAAO, Editor-in-Chief, MSU-COM, Dept. of Osteopathic Manipulative Medicine, A-439 E. Fee Hall, East Lansing, MI 48824.

## **Editorial Review**

Papers submitted to *The AAO Journal* may be submitted for review by the Editorial Board. Notification of acceptance or rejection usually is given within three months after receipt of the paper; publication follows as soon as possible thereafter, depending upon the backlog of papers. Some papers may be rejected because of duplication of subject matter or the need to establish priorities on the use of limited space.

## **Requirements for manuscript submission:**

### **Manuscript**

1. Type all text, references and tabular material using upper and lower case, double-spaced with one-inch margins. Number all pages consecutively.

2. Submit original plus three copies. Retain one copy for your files.

3. Check that all references, tables and figures are cited in the text and in numerical order.

4. Include a cover letter that gives the author's full name and address, telephone number, institution from which work initiated and academic title or position.

5. Manuscripts must be published with the correct name(s) of the author(s). No manuscripts will be published anonymously, or under pseudonyms or pen names.

6. For human or animal experimental investigations, include proof that the project was approved by an appropriate institutional review board, or when no such board is in place, that the manner in which informed consent was obtained from human subjects.

7. Describe the basic study design; define all statistical methods used; list measurement instruments, methods, and tools used for independent and dependent variables.

8. In the "Materials and Methods" section, identify all interventions that are used which do not comply with approved or standard usage.

### **Computer Disks**

We encourage and welcome computer disks containing the material submitted in hard copy form. Though we prefer Macintosh 3-

1/2" disks, MS-DOS formats using either 3-1/2" or 5-1/4" discs are equally acceptable.

## **Abstract**

Provide a 150-word abstract that summarizes the main points of the paper and its conclusions.

## **Illustrations**

1. Be sure that illustrations submitted are clearly labeled.

2. Photos should be submitted as 5" x 7" glossy black and white prints with high contrast. On the back of each, clearly indicate the top of the photo. Use a photocopy to indicate the placement of arrows and other markers on the photos. If color is necessary, submit clearly labeled 35 mm slides with the tops marked on the frames. All illustrations will be returned to the authors of published manuscripts.

3. Include a caption for each figure.

## **Permissions**

Obtain written permission from the publisher and author to use previously published illustrations and submit these letters with the manuscript. You also must obtain written permission from patients to use their photos if there is a possibility that they might be identified. In the case of children, permission must be obtained from a parent or guardian.

## **References**

1. References are required for all material derived from the work of others. Cite all references in numerical order in the text. If there are references used as general source material, but from which no specific information was taken, list them in alphabetical order following the numbered journals.

2. For journals, include the names of all authors, complete title of the article, name of the journal, volume number, date and inclusive page numbers. For books, include the name(s) of the editor(s), name and location of publisher and year of publication. Give page numbers for exact quotations.

## **Editorial Processing**

All accepted articles are subject to copy editing. Authors are responsible for all statements, including changes made by the manuscript editor. No material may be reprinted from *The AAO Journal* without the written permission of the editor and the author(s).



## From the Editor

by Raymond J. Hruby, DO, FAAO



# Osteopathic medicine without OMT: Is it possible?

There are a number of osteopathic web sites on the Internet. In fact, if you have access to the Internet just get into one of the search engines sometime and try searching using simple keywords such as "osteopathy," "osteopathic," and other similar terms. You will be impressed with the results you get just from this relatively simple search. One of the sites you will probably find is an osteopathy listserv that I, for one, find very interesting. There are postings here from people all over the world that are involved in osteopathy in one way or another. If you are interested in joining you can find the site at <http://www.rsc.com/osteo/forum/mailling.htm>. There are some very interesting conversations that go on over this listserv.

An item that came up for discussion recently was whether one could practice osteopathic medicine without using OMT. Oddly enough, there were only a very few postings about what I thought would be an interesting and, possibly, a controversial topic. This seems to me to be a question that we ought to wrestle with, and I am surprised it has not come up before somewhere.

I think there is a reason that not much was discussed on the listserv. I am only guessing, but I think the majority of subscribers to the listserv are the DOs from overseas. Given their scope of practice in their respective countries, it would not be

realistic for them to think about practicing osteopathy without OMT. Manipulation is indeed the centerpiece of their practice, and they would not be without it.

With respect to American-trained DOs however, my guess is we would hear a number of opinions on this subject. While I have never had a conversation with other DOs on this subject, I can think of statements I have heard colleagues make over the years that would seem relevant to this topic. For example, I have heard DOs say that they always do OMT "when appropriate." What does this mean? Osteopathic theory states that there is a somatic component to every disease or condition a patient might have. There are some studies that would support this theory. If this is the case, wouldn't every patient have some kind of somatic dysfunction? Shouldn't that somatic dysfunction be treated? Some would say that the answer is maybe yes, maybe no. It would be argued that if the somatic dysfunction is deemed to be related to the patient's condition and to have enough clinical significance, then it should be treated. One should also remember that OMT might not be appropriate if it is clearly contraindicated in a given patient. Then again, when is OMT contraindicated? While much has been written on this topic, I do not believe there is a clear consensus about contraindications to OMT. Indeed, with all the different

modalities of OMT available, some would argue that there are safe and effective techniques for any patient condition. But I digress.

How do we determine the clinical significance of a somatic dysfunction? If a patient with congestive heart failure has segmentally related somatic changes in the upper thoracic region, this would seem to be clinically significant. But, what if that patient only had altered mechanics of the lower extremity? Is that significant? Is it related to the patient's condition? Should it be treated? Some I have spoken to have said no, others have thought that the altered lower extremity mechanics might constitute a large enough energy demand on that patient's body to perhaps risk further stress to an already compromised cardiovascular system.

What about the osteopathic physician who does not utilize OMT per se, but has an OMM consultant treat all of his or her patients? Is this DO practicing osteopathic medicine? Again, some DOs would say no, while others would say that between the two DOs all of the principles of osteopathic medicine are being considered, and the patient is getting the full benefit of osteopathy.


I think most DOs would agree that osteopathic medicine is much more than OMT, that it is a complete system of medicine based on a unique philosophy and set of principles. At

*continued on page 13*



## Message from the President

by Mark S. Cantieri, DO, FFAO



# Let's direct our energy to advancing the profession

I would like to extend the thanks of the Board of Trustees and the membership of the AAO to Ray Hruby for his dedication and hard work in bringing about *The AAO Journal*. From its inception until the end of this year, he has generously given of his time to create a journal we are all very proud of. Dr. Tony Chila will be the new editor beginning in January. I think we can rest assured that we are being left in very competent hands.

After attending the AOA Board of Trustees' meeting and House of Delegates' meeting in July, I had to ask myself what are the ramifications of family practice (FP) and neuromusculoskeletal medicine (NMM) both being certified in osteopathic manipulative treatment (OMT). I honestly feel that there are more positives to this than negatives. On the negative side is the concern that this will decrease interest from doctors already certified in family practice that in the past would have sat for the NMM board examination. These doctors would subsequently join our organization driving up membership. Will they feel there is still a unique reason for them to do so?

The requirements of the residency in NMM/OMT will provide skills that FP/OMT does not. I think the broader knowledge base required of those individuals in the areas of rehabilitation, anesthesia, orthopedics (both surgical and nonsurgical), occupational medicine, rheumatology and neurology will create a physician unparalleled in treating neuromusculoskeletal disorders. This will push manipulative skills to a new level by improving the differential diagnosis. It will create greater opportunity for residents to interact with a greater variety of physicians creating a larger physician exposure to our skills and resultant referrals for our specialists.

Family physicians should now be held to a higher level of accountability because of their certification in both family practice and OMT. It should be difficult for a physician to say he does not do OMT when his certificate says he is certified in this. I see this as an opportunity for the family physicians to increase the amount of CME devoted

to OMT and an opportunity for the American Board of Osteopathic Family Physicians to put a greater emphasis on the quality of their OMT practical examination. This will only improve the level of care that all patients receive, which is truly important.

For the past several years hard feelings have arisen between the American College of Osteopathic Family Physicians and the AAO. Both organizations naturally have worked to do what they felt was in the best interest of their particular specialty. This has caused us to spend too much energy in conflict rather than directing our total energies to enhancing patient care and unity in the profession. AOA President Eugene Oliveri has called for us to put an end to this battle and focus on the good of the entire AOA organization. To this I say "amen."

The AAO leadership looks forward to working within the framework of the AOA for the betterment of all specialty colleges concerned. We particularly have reason to be excited about an improved residency program and what lies ahead for our specialty. Feeling like we lost something this past year and not supporting the AOA will only distance us from the rest of the profession. Membership support during this transition in our residency and for the Unity campaign will only help the Academy. □

## Cleveland

### It'll Rock You . . .

at the  
AAO  
Annual Convocation  
March 23-26, 2000



Fall 1999



# Message from the Executive Director

by Stephen J. Noone, CAE



## What does certification in neuromusculoskeletal medicine and OMT really mean?

By this time, the reader should already be aware that the American Osteopathic Association's Board of Trustees adopted in July 1999 sweeping changes in the names for both residency training and certification in the disciplines of family practice and osteopathic manipulative medicine. The new title given to FP residencies will be residency training in family practice *and* osteopathic manipulative treatment (OMT). AOA-certified FPs will now receive a certificate in family practice *and* OMT. Similarly, the new title for OMM residencies will be neuromusculoskeletal medicine *and* OMT. DOs who pass the new certification examination will receive certification in neuromusculoskeletal medicine *and* OMT.

What is *neuromusculoskeletal medicine*? In January 1999, the AOA approved the *Basic Standards for Residency Training in Neuromusculoskeletal Medicine*, which included a mutually-acceptable definition of the new specialty approved by the AOA Council on Postdoctoral Training. In July 1999, the definition was amended to include "osteopathic manipulative treatment" as follows:

Neuromusculoskeletal medicine and osteopathic manipulative treatment is that component of medicine concerned with implementing systems in understanding health and disease and managing patients. The practice of neuromusculoskeletal medicine and osteopathic manipulative treatment directs special attention to the structural aspects of body function and their role in all disease processes, along with those strategies prescribed and or administered to enhance homeostasis within the body unit. Practitioners of neuromusculoskeletal medicine and osteopathic manipulative treatment consider and/or incorporate all recognized treatment methods in the management of patients.

The discipline of neuromusculoskeletal medicine and osteopathic manipulative treatment directs spe-

cial attention to the neuromusculoskeletal system and its interaction with other body systems. Neuromusculoskeletal medicine and osteopathic manipulative treatment encompasses increased knowledge and understanding of osteopathic principles and practice and heightened technical skills of osteopathic manipulative medicine, and integrates each of these into the management of pediatric, adolescent, and geriatric patients.

This specialty includes knowledge of anatomy, physiology, and pathology as they relate to all body systems in health and disease, and focuses on knowledge relevant but not limited to the disciplines of neurology, rheumatology, orthopedics, and physical medicine and rehabilitation. Neuromusculoskeletal medicine and osteopathic manipulative treatment involves the development of skills in the use of visual, palpatory, and biomechanical evaluation techniques for improved physical assessment of body disturbances expressed clinically in the neuromusculoskeletal system and in other fundamentally related systems. This specialty integrates the full field of medical and surgical practice with a high level of proficiency in the area of neuromusculoskeletal diagnosis and treatment.

This knowledge of structure and function and palpatory skills are especially relevant in the management of medical and surgical patients with acute and chronic pain and disease in both inpatient and outpatient settings.

*As part of the curriculum outlined in these Basic Standards for Residency Training in Neuromusculoskeletal Medicine and Osteopathic Manipulative Treatment, students learn the philosophy, principles and practice of osteopathic manipulative medicine, including osteopathic manipulative treatment. A core exposure to and preparation in the various models*





of osteopathic manipulative medicine is central to this education process. Upon completion of this residency training program, the graduate has been prepared to undertake the distinctive practice of neuromusculoskeletal medicine and osteopathic manipulative treatment.

In July 1999, the AOA Board of Trustees approved Bylaws amendments for the reconstituted **American Osteopathic Board of Neuromusculoskeletal Medicine**, which assumes responsibility for certification of osteopathic physicians in this new discipline. The direct means for qualifying to sit for examination will be completion of (1) an AOA-approved residency in neuromusculoskeletal medicine and OMT; (2) an AOA-approved *integrated* residency in neuromusculoskeletal/family practice and OMT; or (3) an AOA-approved Residency-Plus-One Option, i.e. one year of study in neuromusculoskeletal and OMT following completion of another residency.

However, until December 31, 2005, any osteopathic physician may qualify to sit for examination in the discipline of neuromusculoskeletal and OMT under terms of the **practice track**, provided that they meet the basic requirements established by the Board and approved by the AOA. Briefly, these requirements are five years of practice (after internship) and the accumulation of 250 hours of continuing medical education, with 150 of those hours in the neuromusculoskeletal discipline approved by the certifying board.

DOs may request an information packet by writing to: American Osteopathic Board of Neuromusculoskeletal Medicine, 3500 DePauw Blvd., Suite 1080, Indianapolis, IN 46268-1136. □

## Affiliated organization's CME calendar...

### September 24-26

*10th Annual Fall Conference*  
Osteopathic Phys. & Surgeons of Calif.  
Monterey, CA  
Hours: 20-22 Category 1A  
Contact: OPSC  
(916) 447-2004

### September 29-October 2

*KCOM's FoundersDay*  
"Academy Awards:  
An Manipulative Update"  
Contact: Rita Harlow, KCOM  
(800) 626-2286

### October 6-10

*59th Annual Convention  
and Scientific Sessions*  
American College  
of Osteopathic Internists  
LaQuinta, CA  
Contact: ACOI  
(800) 327-5183

### October 8-10

*SCTF Continuing Studies*  
"Inside the Neck"  
UNECOM - Biddeford, ME  
Contact: SCTF - Judy Staser  
(817) 926-7705

### October 16-19

*Biodynamics Phase VII*  
Franconia, NH  
Contact: James Jealous, DO  
(207) 778-9847

### February 17-21, 2000


*Mid-Winter Basic Course*  
The Cranial Academy  
Phoenix, AZ  
Hours: 40 Category 1A  
Contact: The Cranial Academy  
(317) 594-0411

### June 17-21, 2000

*June Basic Course*  
The Cranial Academy  
Philadelphia, PA  
Hours: 40 Category 1A  
Contact: The Cranial Academy  
(317) 594-0411

### June 22-25, 2000

*Annual Conference*  
The Cranial Academy  
Philadelphia, PA  
Contact: The Cranial Academy  
(317) 594-0411



By recruiting a new AAO member, you can earn a 10 percent discount on CME course registration or book purchases up to a \$50.00 value.

Why not approach a colleague today and encourage him/her to join you as an active AAO member?

If you do not have an application or promotional materials, contact:  
**AAO office @ (317) 879-1881 or**  
**go to the AAO's website:**  
**<http://www.aao.medguide.net>**



# Five tips for year-end giving

If you are like most people, you do your major giving toward the end of the year. This probably occurs for several reasons. The closing of the tax season encourages itemizers to obtain income tax deductions; a barrage of earnest appeals by nonprofits increases awareness of financial need; and many are simply pre-disposed to end the year by making a charitable gift.

Here are five tips to help you make the most of your year-end giving:

1. Calculate your income. Try to get a handle on your tax liability for the year. Did your unearned income increase? Did you sell any appreciated assets? Will you owe more taxes? This alone may motivate you to increase your giving before December 31. In fact, you may even want to move some of your giving forward from next year to create a larger income tax deduction for yourself this year. Non-itemizers may especially find this "grouping of gifts" useful in order to take advantage of an itemized tax return every other year.

In any case, by the time you fill out your income tax return, it will be too late to make charitable gifts for the previous year. Take the time to do some planning while you still have the opportunity to make a year-end gift.

2. Review your stocks. Look at the stocks you have held for more than a year. Which ones have appreciated the most? It may be prudent for you to make your year-end gift using one or more of these stocks. Here's why: If you sold the stock, you would incur capital gains tax on the appreciation. However, if you give the stock and allow the American Academy of Osteopathy to sell it, no one pays tax. And you get a charitable

deduction for the full amount of the stock, just as you would if your gift was made with cash. And what is more, if you cannot use all of the income tax charitable deduction resulting from the gift, you can carry it forward for up to an additional five years. Such gifts are deductible up to 30 percent of your adjusted gross income.

3. Consider a life-income gift. The Academy offers a variety of life-income plans to fit your needs. You can make a gift now, obtain tax benefits and receive income for the rest of your life. Sound too good to be true? A few minutes of your time will convince you otherwise. Our planned giving officer can provide personalized illustrations and printed material to assist you and your advisor(s).

4. Do your giving early. This is especially true if you want to make a gift of noncash assets (stock, real estate, etc.). It also applies to life-in-

come gifts (gift annuities, pooled income fund contributions, trust arrangements, etc.). Your professional advisor(s) and planned giving officers are busy beyond belief as the year winds down. The sooner you can get your gift activity going, the better it will be for everyone concerned.

5. Talk to your advisor. Before making any significant gift to the Academy, or to any other nonprofit for that matter, you should have your CPA, attorney or other advisor help you understand the impact of your gift on your income tax return and estate. We at the Academy want your giving to be prudent, as well as generous and joyful.

For more information about the year-end giving opportunities at the Academy, contact Executive Director Steve Noone; or complete and mail the coupon below. We are here to help you in any way we can.

(Please complete and return this reply form.)

Dear Friends at the American Academy of Osteopathy:

- Please send me information about year-end giving.
- Please contact me about a personal visit or other assistance.
- I have provided for the Academy in my will or other estate-planning document.
- Please send me information about the Academy's planned giving programs.

Name: \_\_\_\_\_

Address: \_\_\_\_\_

City: \_\_\_\_\_

State: \_\_\_\_\_ Zip: \_\_\_\_\_ Phone: \_\_\_\_\_

Mail this form to:

**The American Academy of Osteopathy,**  
3500 DePauw Blvd., Suite 1080, Indianapolis, IN 46268-1136.



### Case study:

# Osteopathic manipulative treatment of an 8-year-old child born with anoxia

by Mary Anne Morelli, DO, CSPOMM, Osteopathic Center for Children, San Diego, CA

### *Patient Identification:*

R.W. – an eight-year-old Caucasian male

### *Chief Complaint:*

Patient had difficulty with fine and gross motor skills and had eye muscle imbalance. He did better with verbal than with written work and was very smart, but a “watcher.”

### *History of Chief Complaint:*

Although R.W. was very social and did well in school, his mother felt that in some manner that she could not quite put her finger on, he was not functioning optimally. She believes this may go back to his early events. He also has occasional (hammerlike) headaches.

### *Past Medical History:*

R.W. was born to a 27-year-old mother in good health. There was no history of medications, drugs, or alcohol. Labor began two weeks early at 2 am and progressed rapidly. Membranes ruptured at 7 am and the baby was born at 9 am. No medications were used. His head was markedly molded and his color was blue, requiring oxygen. Nursing was attempted and he was able to latch on well. He was taken to the special care nursery later for observation due to episodes of cyanosis. An I.V. was started and oxygen given. A cardiology exam revealed transposition of the great vessels. Prostin was given to keep the ductus open. On day 9, a “switch” operation was performed. He had a heart attack after the surgery. R.W. was discharged to home at 3 1/2 weeks of age. Medications for the first year of life

included Lanoxin and Lasix. His weight gain was slow. He nursed until 14 months. Immunizations were up to date. R.W. did have a low-grade fever after several of the immunizations. He had occasional colds, otitis media, and a rare cough.

### *Past Surgical History:*

At 9 days, a “switch” operation for transposition of the great vessels was done. At 10 months his left eye began to drift. He required 3 ocular surgeries (Left eye -2, right eye -1). At age 2 1/2 the pulmonic artery was surgically enlarged to prevent pulmonic stenosis.

### *Social History:*

R.W. lived with his 35-year-old mother and 36-year-old father. Both were in good health. There was a family history of hypertension and obesity. *Development.* R.W. sat at 7 months, crept at 8 months but was not as skilled at creeping as his sister. He preferred cruising and did walk alone at 14 months. He talked at age 2 1/2 years. At age 4, he fell off a play structure, cutting his head in the occipital area. Although his vision was poor and he read with a contact, he was doing well academically in the 3<sup>rd</sup> grade.

### *Allergies:*

No Known Medications: None presently

### *Physical Examination:*

Weight 58.5 lbs; Height: 51"; Temp. 98.2°F; Pulse 80; Respiratory Rate 20. His right foot externally rotated when

walking, skipping was fair. When creeping (crawling on hands and knees), there were 4 distinct sounds indicating a lack of integration of the extremities. During creeping there should be only 2 sounds as the right knee and left hand touch; then the left knee and right hand touch the ground. was disorganized and he used his arms more than legs. Pes planus was present with bilateral bowing of the Achilles tendon. The left ear and left shoulder were down, the left scapula was down and slightly winged. Head was held to the right with shoulders forward. Forward flexion was 4" from the floor with midthoracic flattening. The left thorax showed a slight hump. Balance was difficult especially on the left foot. Tympanic membranes were retracted bilaterally. He had a high palate with .05 mm open bite. The centrals were separated and jaw deviated to the left. He had a flow heart murmur at the lower left sternal border. There was a thick midline scar. Lungs were clear to auscultation. Thoracic diaphragm was restricted with increased thoracic tension. Abdominal fascia was tense. There was no hepatosplenomegaly. Right eye turned in more with an upward gaze. Left eye turned in more with near-point focusing. Tracking was difficult. Throat showed lymphoid studding. Anterior cervical lymphadenopathy was present. Eyes had circles underneath. The nose deviated slightly left and the nasal mucous was boggy with mouth breathing. The left leg showed decreased internal and external rotation. The straight leg raised left 75° and right 80°. The left thigh was 29.5 cm and right thigh 30.5 cm. Muscle spasms



were present in thigh and knee region. *Babinski test:* Left great toe downgoing then up; right downgoing.

The gastrocnemius were tight bilaterally with lumbosacral compression. The sacrum was very hard and it pulled up on the left while rotating on the anterior/posterior axis. The right anterior superior iliac spine was down. Grip strength was less on the left. Reflexes were 1+4 bilaterally upper and lower. Head was compressed with superior vertical strain. Metopic structure was very restricted.

#### *Initial Assessment:*

Motor cerebral dysfunction; plagiocephaly; eye muscle imbalance; somatic dysfunction of the head, cervical, thoracic, lumbar, and sacral regions, and upper and lower extremities.

#### *Treatment Plan:*

Eight weekly treatments were recommended. Vision therapy would be considered later.

#### *Course of Treatment:*


Over a period of eight weeks of weekly treatments, the whole body was addressed beginning with a venous sinus technique to begin decompression of the cranial mechanism. Subsequent visits included: lumbosacral and sacroiliac decompression and gluteal fascial release to decrease restrictions in pelvis and legs. According to Dr. Frymann, freeing the gluteal fascia is very important in children with cerebral palsy type symptoms. Occipito mastoid release by V spread and sphenobasilar symphysis decompression and parietal lift were done to further free the cranial mechanism. Intraoral techniques to address the high palate and overbite were done. Mediastinal fascia release was done due to the effects of the scar which exacted a pull into itself. Orbital techniques were done to improve eye function. In our work with developmental optometrists, treating the cranial mechanism improves visual function prior to their

therapy. They often send a child for treatment prior to vision therapy to remove any structural component that can be addressed.

#### *Discussion:*

A young child will draw a picture of his body as it feels to him. R.W. drew me a picture that showed his right side to be much larger than his left. In reality, his right side was much stronger. After I completed the physical exam, I saw the picture. I asked him if one arm or leg was stronger, and he stated that his right arm and leg were much stronger so he drew them larger. The picture he drew after a course of treatment showed a different body perception. R.W.'s mother reported an improvement in his overall health and a decrease in headaches. R.W. continues to receive intermittent treatment to decrease the damage to the motor tracks that can be injured by spontaneous bleeds most often associated with premature births, or in this case, by anoxia. □

*Drawn on September 6, 1994*



*Drawn on November 18, 1994  
after (8) Treatments*



# *Introduction to OMT with Soft Tissue Articulatory Techniques*

Western University – College of Osteopathic Medicine of the Pacific

November 12-14, 1999

**CME Hours: 20**

**Program Faculty:**

Walter Ehrenfeuchter, DO, FAAO, Co-Chair

**Abstract:**

This course is an Introductory Level Course in Basic Osteopathic Principles and Practice. It is designed for M.D.s who have no experience in the field, and for D.O.s whose Manipulative Medicine skills have long lay dormant. Diagnostics for the axial skeleton will be integrated over 3 days with with Basic Soft Tissue and Articulatory Techniques. A pot pourri of other Osteopathic Manipulative Techniques will serve to expose course participants to some other aspects of Neuromusculoskeletal Medicine.

## Program

**Friday, November 12**

- 7:30 am Registration
- 8:00 am History of Osteopathic Medicine
- 8:30 am Philosophy of Osteopathic Medicine
- 9:00 am Introduction to Somatic Dysfunction
- 10:00 am Break
- 10:15 am Physiologic Basis for Soft Tissues and Articulatory Techniques
- 11:15 am Palpation
- 12:15 pm Lunch
- 1:00 pm Cervical Spine – Mechanics and Structural Diagnosis
- 2:00 pm Cervical Spine – Soft Tissue Technique
- 3:00 pm Break
- 3:15 pm Cervical Spine – Articulatory Technique
- 4:15 pm Cervical Spine – Other Techniques
- 5:00 pm Adjourn for the Day

**Saturday, November 13**

- 8:00 am Thoracic Spine – Mechanics and Structural Diagnosis
- 9:00 am Thoracic Spine – Soft Tissue Technique
- 10:00 am Break
- 10:15 am Thoracic Spine – Articulatory Technique
- 11:15 am Thoracic Spine – Other Techniques
- 12:00 pm Lunch
- 1:00 pm Ribs – Mechanics and Structural Diagnosis
- 2:00 pm Ribs – Soft Tissue Techniques
- 3:00 pm Break
- 3:15 pm Ribs – Articulatory Techniques
- 4:15 pm Ribs – Other Techniques
- 5:15 pm Adjourn for Day

**Sunday, November 14, 1999**

- 8:00 am Lumbar Spine – Mechanics and Structural Diagnosis
- 9:00 am Lumbar Spine – Soft Tissue Techniques
- 10:00 am Break
- 10:15 am Lumbar Spine – Articulatory Techniques
- 11:15 am Coding – How to code properly, report and document your services for third party payers.
- 12:00 pm Course Summary
- 12:15 pm Adjourn

**Suggested Text:**

*Foundations for Osteopathic Medicine*  
Pub. by Williams & Wilkins

**Dress:**

Loose fitting sports attire, jogging attire, etc.

### Registration Form

Intro to OMT and Soft Tissue/Articulatory, November 12-14

Full Name \_\_\_\_\_

First Name for Badge \_\_\_\_\_

Street Address \_\_\_\_\_

City \_\_\_\_\_ State \_\_\_\_\_ Zip \_\_\_\_\_

Phone # \_\_\_\_\_ Fax \_\_\_\_\_

AOA # \_\_\_\_\_ College/Year Graduated \_\_\_\_\_

I require a vegetarian meal

#### Registration Rate:

AAO Member	\$450
Intern/Resident	\$250
AAO Non-Member	\$550

AAO accepts VISA OR MASTERCARD

Credit Card # \_\_\_\_\_

Cardholder's Name \_\_\_\_\_

Date of Expiration \_\_\_\_\_

Signature \_\_\_\_\_



# Letter to A.T. Still

Dear Doctor Still,

We have spoken before about a question that comes into the mind of every osteopathic physician at one time or another: How often should a patient be treated? The obvious answer is that it depends on the nature of the patient's problem, and with experience, we all understand how that principle applies. There is no simple answer to this question. Very complex conditions sometimes respond to only a few treatments, and at other times require months of effort. There is no rhyme or reason for this; and why is that? I think it is because if we only look at diseases or conditions and try to come up with a "cookbook" answer for the number of treatments it takes to resolve each one, we will always be troubled for an answer. But, if we use our osteopathic abilities to observe, listen, and palpate, we can know much more precisely whether or not the patient is responding to treatment, and when the patient is well on the road to recovery. I am reminded of some words in your *Autobiography* (p. 202), where you said: "To make the sick well is not the duty of the operator, but to adjust a part or the whole of the system in order that the rivers of life may flow in and irrigate the famishing fields. We should stop and consider at the point of irrigation how often the mains should be opened to supply the ditches and how long the sun of life should shine upon that crop, doing its duty of nourishing and vitalizing it according to individual demands. I have said to heal the sick is a duty that belongs to another division of Operators, and not the hewers of timber nor to muscles of force, but to the rivers of life only. To irrigate too much is as detrimental as too little or not at all. How much? Is the all-important question to solve. The kind and quantity of fluid or force must be supplied at the right time and place only."

We cannot always have a direct answer to the question about how often to treat someone. However, if we plan our approach to patients based on sound osteopathic thinking, we can feel more confident that we will treat every patient sufficiently and properly.

Your ongoing student,  
Raymond J. Hruba, DO, FAAO

## NEW ENGLAND

Interested in OMT, family medicine and woman's health? Be assured of being busy by joining this well-established private practice closed to new patients. New office located next to well-equipped/staff hospital. College city close to ski resorts and the coast. Contact Doug Page at Lawlor & Associates by phone (800) 238-7150; fax (610) 431-4092; or email Lawlor Rctg@aol.com.

*continued from page 5*  
*Message from the Editor*

the same time there are those DOs who feel that OMT is the hallmark of osteopathic medicine and is precisely what makes us distinctive.

Can we practice osteopathic medicine without OMT? What do I think about this question? One thing seems clear: osteopathic medicine as a profession would not be osteopathic medicine without OMT. But, whether an individual DO can apply the principles of osteopathy to a given patient and not use OMT remains a topic that, in my experience, invites a wide range of opinions from DOs. I personally utilize OMT on virtually all my patients. I believe that the decision to utilize or not to utilize OMT is based on thoughtful consideration of the patient in light of the unique principles of osteopathic medicine, and a way of viewing the human body that is distinctively different from other approaches. These other osteopathic principles are more cognitive in nature, and thus are not so observable as OMT. This is perhaps what brings about the wide range of answers to my question. I would love to see a symposium dedicated to just this topic.

Can one practice osteopathic medicine without using OMT? What do you think? □

## DIRECTOR OF OSTEOPATHIC MEDICINE

Our reputation for excellence and progressive thinking has placed Mount Clemens General Hospital at the forefront of the most respected health care organizations in the Midwest. We believe in success based on professional integrity and smart strategies and we're actively seeking a motivated, talented and experienced Director of Osteopathic Medicine to share in our continued successes.

This high level position will be responsible for developing and implementing an effective Osteopathic Principles and Practice program, reviewing and implementing policies in the Osteopathic medicine services, and performing teaching duties to various staff and students. Other duties include evaluating personnel performance and providing inpatient/outpatient consultations.

The successful candidate will be an Osteopathic physician with a fellowship and/or residency training in Osteopathic Manipulative Medicine and have Board certification through the American Academy of Osteopathy. Must maintain an active license to practice Osteopathic Medicine in the State of Michigan. Previous educational experience in Medical Education is preferred.

We offer an outstanding benefits package and salary commensurate with experience. Please send resume and salary history to: **Tom Stackpoole, One Sterling Town Center, 12900 Hall Road, Suite 400, Sterling Heights, MI 48313; Phone: (800) 680-2874 or (810) 741-4080; Fax: (810) 412-9472.** An equal opportunity employer.



**Mount Clemens  
General Hospital**



# Letters to the Editor

Dear Editor:

I read your article in the AAO Journal today, and wanted to communicate with you about it. Your thoughts were especially interesting to me as I too have been studying and contemplating perception as the central aspect in understanding the phenomenon of healing. Also, I found the discussion of metaphor with respect to The Tide to be very helpful. All in all, I thought it was a heuristic article. I'm sure many persons will find benefit in reading it, as I did.

I want to suggest one thing to you about your use of physics as an example of science. Physics, and in particular, cosmology, now seems to be taking the discipline more and more into the phenomenological realm, into an exploration of the mystery of the universe. Recently, in an issue of *Scientific American*, an excellent article on cosmology appeared which discussed the whole issue of the energy in the cosmos as having an extremely powerful role in determining the behavior of what heretofore had been the focus of cosmologists: matter. Its power apparently far outweighs that of any gravitational forces or attributes that could be traced to the matter in the universe. The explanations for this have clearly crossed into the metaphysical and mystical realms. The whole field of physics is undergoing a transformation as a result, not only of cosmology, but because of the new ideas that have come as a result of the implications of quantum physics and the concept of relativity. In fact, the "cosmological constant" that is placed in the  $E=mc^2$  equation is the energy factor that is being referred to in the *Scientific American* article. Much has happened in the last 50 years in physics. Now another scientific revolution is happening which has changed

perceptions of reality in the field dramatically, as Kuhn describes.

There is a wonderful book for the educated layman about physics and these new ideas that was responsible for my change in understandings about physics. It is called, *The Dancing Wu Li Masters*, by Gary Zukav. I put the reference at the bottom of this letter. His newer book, *The Seat of the Soul*, carries these concepts even further. It is truly fascinating, and surely applies to the practice of Osteopathy, as you discuss in your article.

I hope you find this information helpful. I really appreciate your writing the article, and hope we have the opportunity to meet and talk more about your ideas. It seems we are learning about similar things in our ongoing education.

Sincerely, David N. Grimshaw, DO,  
CSPOMM, Assistant Professor  
MSUCOM

Zukav, Gary. *The Seat of the Soul*, Simon and Schuster, 1989.

Zukav, Gary. *The Dancing Wu Li Masters*, Wm. Morrow and Co., NY 1979.

Dear Editor:

I very much appreciated Dr. Masiello's essay "Osteopathy - A Philosophical Perspective: Reflections of Sutherland's Experience of the Tide." As an osteopathically inclined MD, I have for a long time felt that there was something missing in my rather hit-or-miss osteopathic education. Dr. Masiello's article filled a large gap and helped me to understand some of the consequences of applying Still's and Sutherland's teachings to my own practice of medicine.

In fact in the area of research, I have often wondered if inter-examiner

reliability studies are not impossibility in osteopathy. I suspect that the more skilled the examiners, the more likely the physical findings will change between examinations. If I understand Dr. Masiello correctly, phenomenological principles might explain this paradox.

I would be interested to know if other members of the Academy have come to similar conclusions.

Robert Kidd, MD,CM,  
<robkidd@renfrew.net>

Dear Editor:

Your "From the Editor" in *The AAO Journal*, Summer '99, Volume 9 #2 on the use of the "Tide" for cervical spine mobilization is most interesting and stimulating.

The article by Domenick Masiello, D.O. in the same volume is also most interesting and refreshing.

If we were to add "Esoteric Healing" to the two above formulas we should be able to see that the use of "entrained energy" really has no limits in the healing process except what we place upon it as individuals.

Regards,  
Richard C. MacDonald, DO  
North Palm Beach, FL

Dear Editor:

I wish to acknowledge the letter in the Volume IX, No. 2 issue of the Summer 1999 *AAO Journal*, submitted by Martyn E. Richardson, DO, FACOP. In addition to his words of wisdom concerning shortleg syndrome, Dr. Richardson presented some very interesting historical information.

I certainly agree that anatomic short



leg often goes undiagnosed, and is an important contributor to recurrent somatic dysfunction and pain. Any time somatic dysfunction or back pain fails to respond to routine OMT, anatomic short leg should be a consideration. It is easy to diagnose with a standing, functional pelvic series x-ray using the protocol outlined by Willman (*Journal AOA*, Vol. 76, June 1977).

I would further like to draw to the attention of all those interested in the professional aspects of short-leg syndrome, a recent landmark manuscript entitled "The Origin and Relief of Common Pain" by Robert Edwin Irvin, DO, recently published in the *Journal of Back and Muscular Rehabilitation*, No. 11 (1998), 89-130. This excellent, comprehensive publication underscores the importance of postural considerations as underlying cause of recurrent back pain.

Sincerely,  
Dale E. Alsager, DO, PhD,  
Maple Valley, WA

Dear Editor:

I am writing in reference to the fall of 1998's, "Student's Corner." While I applaud Ms. Lai's courage to undertake the writing of a case report, I did find several things lacking. First of all, where was the thorough history and physical? She completely lacked any evaluation of the visceral system. Though the patient had a history of orthotic usage, what about gynecological or gastrointestinal issues, or at least a Review of Systems showing that they were at least thought of? Secondly, where was the neurologic exam? Thirdly and probably the most blatant, was Ms. Lai's lack of any level of extremity exam, especially when the patient's past history is highly significant for trauma to the side found inferior on the postural x-ray. There was also no mention of the

pelvis. My biggest question, however, is why was this case allowed to be published? As a fourth year student and OMM fellow, I have done my share of poor exams and H&Ps. I have also been told my mistakes and have tried to be more thorough since. I never at anytime would have sent my cases in for presentation. If I had sent a similar case in, I would have at least expected to get it back for corrections. Ms. Lai's case is representative of many students' misunderstanding that osteopathy is just the axial spine. How do we change their perception when we allow a case like hers to be published? If there is to be a Student's Corner, I would venture to say that it should only contain the best, ideal forms of presentations, which represent the total body view of osteopathy, or at least exam the problem thoroughly.

John Rickelman, Jr., MS-IV  
KCOM



## AAO Coding Information Packet

### Contact:

American Academy of Osteopathy  
3500 DePauw Blvd., Suite 1080  
Indianapolis, IN 46268-1136  
Phone: (317) 879-1881 or  
FAX: (317) 879-0563

Send: \_\_\_\_\_ # of packets @ \$15.00 each to:

Name \_\_\_\_\_

Street Address for UPS Shipment \_\_\_\_\_

City, State, Zip \_\_\_\_\_

Daytime Phone \_\_\_\_\_

### AAO Accepts MasterCard or Visa!

Card Number \_\_\_\_\_

Expiration Date \_\_\_\_\_

## PHYSICIAN

A full-time faculty position is immediately available for a board-certified/board-eligible Doctor of Osteopathy at the University of North Texas Health Science Center – Texas College of Osteopathic Medicine in Fort Worth. Teaching osteopathic manipulative medicine is required. Clinical and research opportunities are available. Competitive salary and excellent benefits package. Letters of interest should be sent to:

Scott T. Stoll, DO, PhD,  
Interim Chairman/Assistant Professor  
c/o Elisa Bircher  
University of North Texas Health Science Center  
3500 Camp Bowie Boulevard  
Fort Worth, Texas 76107-2699

817/735-2461 • Fax 817/735-2270

An EEO/Affirmative Action Institution



# Health services research: Evidenced-based medicine and the AAO five-year strategy

by Albert F. Kelso, PhD and Deborah M. Heath, DO

The AOA agenda for the 21st Century and the AAO five-year strategy is an opportunity for practicing DOs to participate in providing evidence on total benefits of osteopathic health care for patients. The contribution of DOs on research teams conducting clinical studies and clinical trials is necessary and increases contributions to specific details of osteopathic health care. (Frymann, Mills). The contribution from practicing DOs that we propose provides evidence from practice that relates the procedures used in providing a patient's health care to the general and specific health benefits attained. This is medical outcome research that we will identify in future articles as *Health Services Research*.

Adding a second clinical research agenda, *health services research*, to existing research on osteopathic health care will support any image created by marketing efforts. Equally important is that *Health Services Research* gives evidence on the total benefits of osteopathic care obtained by patients. This information is recorded and published as aggregated data that protects the individual's privacy. Important information on the osteopathic profession's goal for restoring and maintaining a patient's health while addressing specific patient health problems is gained. This concept of total health care as part of osteopathic practice, poorly understood outside the profession, is documented from data on practice. Classical clinical research advances osteo-

pathic care for illness. Support for osteopathic practice, as well as osteopathic theory and philosophy, is obtained by *health services research*. Such data on optimum care requires reliable grass root data from the practices of DO family practitioners and specialists.

We suggest that the AAO supply

---

*The contribution of DOs  
on research teams  
conducting clinical studies  
and clinical trials  
is necessary and increases  
contributions to specific details  
of osteopathic health care.*

---

the infrastructure and support for the effort as part of the unified effort. The AAO's support for previous data collection on post-doctoral education indicates that a similar commitment for the first year or two will enable *health services research* to be developed. Practicing DO family clinicians and specialists will need education, training and guidance to justify their time and effort in providing the medical record data and reports for input to the proposed system. We can, within the immediate future, supply background information, models for data collection, a central database for reports, and creating a central clearing station for questions. As this point we have sufficient background and experience to establish a central da-

tabase and an infrastructure for developing and maintaining *health services research* as a compliment to classical basic and clinical research on osteopathic medical concepts.

We need input on the planning and implementation of *health services research* from the DOs who may participate. Send your comments – reservations, suggestions, and specific ideas to Louisa Burns Osteopathic Research Committee, American Academy of Osteopathy, 3500 DePauw Boulevard, Suite 1080, Indianapolis, IN 46268-1136. These comments will be included in planning a *health services research* series of articles on implementing an AAO data collection system.

In your comments consider the following questions. Will *health services research* provide evidence-based data on our image as health care providers? Do you see this data as needed for informing the public and governmental agencies? Is it important to include total health outcomes on the nature and effectiveness of osteopathic medical services provided for patients? Is it feasible to expect practicing DOs and their patients to participate in *health services research*? Does including total health outcomes as part of a patient's benefit from osteopathic health care improve our image? Is change in physical, mental, or social health an important health benefit? Is this important information to support osteopathic theory and clarify the role of the somatic component in a patient's health and illness? □



## From the Archives

# From *Philosophy of Osteopathy*

pgs 260-262

### Lymphatics and Fascia

I have thought for many years that the lymphatics and cellular system of the fascia, of the brain, the lungs, and the heart throughout the whole system of blood supply, do get filled up with impure and unhealthy fluids, long before any disease makes its appearance, and that the procedure of changes known as fermentation, with its electromagnetic disturbances, were the cause of at least ninety percent of the diseases that we labor to relieve by some chemical preparation called drugs. When I was fully satisfied that we were liable to do more harm than good with such remedies, I began to hunt for more reasonable methods to relieve the system of its poisonous gases and fluids, through the excretory system which we had hoped to renovate and purify the system.

### A Satisfactory Experiment

For twenty-five years I have tried to balance myself, divert my mind from all previous methods and see if I could not get more directly to the lymphatic system of nerves, and cause the millions of vessels known to exist in the body to begin to unload their contents and continue that action until all impurities were discharged by way of the bowels, lungs, kidneys, and porous system.

### Natural washing out

At the conclusion of this philosophy I will endeavor to explain just how nature has provided to ward off

diseases, by washing out before fermentation should set up in the lymphatics, from being received and retained the length of time, that destructive chemical changes would begin its work of converting elements into gas and discharging them from the system as unsuitable for nutriment. In order to avoid this calamity we are met with two important thoughts, one of the power of the nerves of the lymphatics to dilate and contract, also that of fascia and muscle, to dilate or constrict with great force when necessary to eject substances from gland, cell, muscle, and fascia. Thus we see a cell loaded to fullness by secretion which it cannot do without; open-mouthed vessels through which it receives this fluid. Then again the system of cellular sphincters must dilate and contract in order to retain the fluids in those cell-like parts of the body. Now we are at the point when ready for use in other parts of the system, those sphincters must temporarily give away, that the gland may relax and dilate. Then the universal principle of constriction throughout the whole body can discharge the contents of the lymphatics of all divisions of the body, which is surely the normal condition. Let the lymphatics always receive and discharge naturally. If so we have no substance detained long enough to produce fermentation, fever, sickness, and death.

I think this thought has been presented plainly enough to be fully understood and practiced by the reader, if an Osteopath.



### AAO Coding Information Packet

Please mail or FAX this form  
along with your order to:

American Academy of Osteopathy  
3500 DePauw Blvd., Suite 1080  
Indianapolis, IN 46268-1136  
Phone: (317) 879-1881  
FAX: (317) 879-0563

Send: \_\_\_\_\_ # of packets @ \$15.00 each to:

Name \_\_\_\_\_

Street Address for UPS Shipment \_\_\_\_\_

City, State, Zip \_\_\_\_\_

Daytime Phone \_\_\_\_\_

FAX \_\_\_\_\_

Charge my:



OR



(circle one)

Cardholder's Full Name  
\_\_\_\_\_

Card Number  
\_\_\_\_\_

Expiration Date  
\_\_\_\_\_

Authorized Signature  
\_\_\_\_\_



### Case study:

# Low back pain in pregnancy

by Kevin M. Gallagher, MS-III, University of North Texas Health Science Center at Fort Worth  
/Texas College of Osteopathic Medicine

## Introduction

Back pain during pregnancy has been known to exist since ancient times. Cantin, in 1899, described symphysiolysis to be the most neglected problem during pregnancy.<sup>9</sup> In 1934, Abrahamson et al described symphysiolysis to originate from all three pelvic joints.<sup>9</sup> Farbrot, in 1952, described the widening of the pubic symphysis and a correlation between back pain and the inclination of the sacrum.<sup>9</sup>

Back pain is very common in pregnant women and often leads to a significant amount of time the woman is away from work and sometimes it can be incapacitating. It is so common that most women expect to experience it. Unfortunately, many physicians dismiss this pain as normal and may consider their patients malingering and usually disregard the possibilities of any treatment or concern. However, in most instances, simple, conservative, non-invasive modalities can be used to minimize the patients pain.<sup>6</sup> The osteopathic physician has the opportunity to normalize the spinal complex and thus influence the homeostasis of the column, which has been altered.<sup>7</sup> As a result, the physician can reduce the patients discomfort by simple procedures and make the pregnancy more enjoyable for the woman.

## History of chief complaint

This is a 33-year-old white female who came to the manipulative medi-

cine department with a complaint of low back pain. She is gravida 1, para 0 and is approximately 19 weeks pregnant with a 10-pound weight gain. The patient states that there exists a sharp pain in her lower right back that intermittently radiates to the left lower back and down the right leg. The patient rates the pain as usually a 7 on a scale of 1-10, but it is only a 3 this morning. She states that the pain is worse at the end of the day and began as soon as she became pregnant. The pain is usually aggravated by walking, sitting for long periods of time and exercise and seems to be lessened with stretching (which she preforms daily), sleep and tylenol. The patient also complains of long-standing neck pain (over 25 years associated with a gymnastics neck and upper back injury) and intermittent headaches with the pregnancy. The patient was also seen in the manipulative medicine department at 9 weeks of pregnancy and stated that the treatment was successful for a couple of weeks.

## Past medical history

The patient has been coming to the manipulative department since April of 1995 for the treatment of a gymnastics injury that occurred in her early teens. She demonstrates a history of recurrent lower cervical and upper thoracic somatic dysfunction along with a left sacral shear and non-neutral mechanics of L5. She also has a history of anterior rotation of her

left innominate and a chronic left flat foot. Recently, since December of 1997, she has been demonstrating somatic dysfunction, in addition to the previous dysfunction listed, of the lower thoracic and lumbar regions. The patient denies any other significant medical problems

## Past surgical history

None

## Social history

The patient denies any smoking, drinking or taking any illicit drugs.

## Allergies

NKDA

## Medications

Prenatal vitamins and tylenol.

## Review of systems

The patient's review of systems mainly applies to her chief complaint. The patient also complains of intermittent headaches since the beginning of the pregnancy.

## Physical examination

### General

This is a 33-year-old white female who is alert, oriented, and cooperative.

### HEENT

Pupils are equally round and reactive to light. Extraocular movements are intact



### *Extremities*

Both upper and lower extremities show full range of motion without tenderness.

### *Neurologic*

CN II-XII are grossly intact without lateralization. Deep tendon reflexes are 2/4 in both upper and lower extremities. No sensory or motor deficits were present.

### *Musculoskeletal*

The patient exhibits a decrease in kyphosis and increased lordosis with lateralization to the left. The patient exhibited an elevated left shoulder and equal iliac crests and medial malleoli. The patient exhibited bilateral lower cervical (C5-C7 region) and lumbar (L2-L5 region) tenderpoints and tissue texture changes. The patient exhibited minimal restrictions in range of motion in the cervical and lumbar regions. The patient also exhibited a left sacral shear (severely decreased left ILA) and a left innominate rotated anteriorly (left decreased ASIS and increased PSIS).

### **Assessment**

- 1) Somatic dysfunction lumbar and cervical region
- 2) Left sacral shear
- 3) Left innominate rotated anteriorly
- 4) 19 weeks pregnant

### **Plan**

- 1) Myofascial release lumbar and cervical region
- 2) Inhibition lumbar region
- 3) Muscle energy - springing, lateral recumbent, left sacral shear
- 4) Pubic decompression
- 5) Muscle energy right elevated first rib
- 6) Condylar decompression
- 7) Jones-strain counterstrain tenderpoints in cervical region
- 8) Pregnancy stretches
- 9) Follow up in 3 weeks

## **Review of literature**

The pelvis is the main foundation upon which the entire spinal column is balanced.<sup>7</sup> During pregnancy the enlarging uterus shifts the body's center of gravity forward, which increases the lumbar lordosis and weakens the abdominal muscles. This increases the stress placed upon the facet joints and posterior ligaments of the lumbar spine and necessitates excessive muscle strain to maintain proper balance.<sup>6</sup> In addition, a hormone called relaxin, is produced during pregnancy in order to prepare the sacroiliac joints to gradually stretch so that the fetal head can fit through the pelvic outlet. This relaxation of the ligaments can result in instability of the joints and a mechanically unstable pelvis.<sup>6</sup> It has been found that approximately 14 percent of pregnant women met diagnostic criteria for sacroiliac subluxation.<sup>2</sup> Therefore, it appears that the combination of the extra stress applied to the lumbar spine along with the laxity of the pelvic ligaments could result in the back pain experienced during pregnancy. However, this still remains controversial.

It has generally been found that over 50 percent of pregnant women suffer from low back pain<sup>10</sup> and that 70.4 percent of women experience back pain during labor.<sup>5</sup> It has been demonstrated to be more common in women who experienced back pain in earlier pregnancies and less common in well-fit women. The pain is usually located in the low back and gluteal areas and can be associated with radicular symptoms. It is usually described as a dull ache in the back and a stabbing pain in the gluteal area. It is often described as intermittent and aggravated by such things as activity, bending forward and overdoing things.<sup>11</sup> The pain tends to limit the amount of time the women can participate in activities. The pelvis has also been described as locking up at times making walking

very difficult and even resulting in an audible pop.<sup>11</sup> Although radicular symptoms often accompany low back pain during pregnancy, herniated disks are generally not thought to be the cause. Lumbar disk disease has been reported to be the result of pregnancy at an incidence of 1 in 10,000.<sup>14</sup> It also has been reported that 53 percent of pregnant women and 54 percent of nonpregnant women have disc abnormalities.<sup>10</sup> Thus, disk disease does not appear to be more prevalent in pregnant women. It is possible that direct pressure of the fetus on the lumbosacral nerves is the cause of the radicular symptoms.

It is obvious that low back pain is very prevalent in women during pregnancy and the problem there lies in relieving the pain to allow for a more enjoyable pregnancy. The first tenet in medical management of the pregnant patient is to minimize the use of all medications. Drug therapy should always be considered as potentially harmful to the mother, the fetus and the course of pregnancy. Nearly all medications reach the fetus to some degree.<sup>10</sup> Therefore, it is in the best interest of the pregnant mother and the fetus to use nonpharmacologic therapies. Traditionally, low back pain during pregnancy has been ignored by the physician and thought of as something that is normal in pregnancy. It has been treated by limiting the women's activities, such as avoiding stairs, extreme movements and overloading the pelvis, and by the use of Tylenol. In severe situations, low back pain has been treated by pelvic belts, crutches or bed rest. There exist many simple, conservative, non-invasive modalities that can be used to minimize the patient's pain and make the pregnancy more enjoyable for the female. Osteopathic manipulation has been used for years in order to relieve the symptoms of low back pain in pregnant females and

→



recent investigations are beginning to statistically document its effectiveness. However, many physicians still do not use the simple techniques of manipulation in the treatment of low back pain in pregnant females for several reasons:

1) Many medical practitioners are skeptical about manipulative therapy and associate it with only short term relief.

2) The orthopedic literature traditionally taught that the sacroiliac joints do not move and therefore should not be considered as a source of pain.

3) Low back pain lies outside most obstetricians' area of expertise.

4) Most obstetric practitioners do not have low tables to use for manipulation, and

5) Physicians feel the lack of time available to treat the patient with manipulation.<sup>2</sup> This is unfortunate since the skills of manipulation in the treatment of low back pain during pregnancy can be learned relatively easily and require only simple equipment.

The obstetric patient poses many treatment difficulties to the physician. The presence of the fetus eliminates the ability to diagnose and treat the patient in the prone position and limits the use of many direct techniques, especially techniques that involve HVLA, in the lumbar and pelvic region. HVLA techniques may induce injury/strain to ligaments in the body that are already loose secondary to relaxin.<sup>13</sup> In addition, supine techniques may also be complicated by the compression of the abdominal vasculature by the large gravid uterus.<sup>13</sup> It is generally accepted that the Pneumatic hammer and the Aquamed should not be used in the obstetric patient. This is due to the potential complications to the fetus by the vibratory motion and due to the potential of the release of oxytocin in the mother which can induce premature labor.

There have been many recent investigations documenting the ease and effectiveness in treating low back pain and sacroiliac disorders in the pregnant female. The pain commonly described as low back pain is thought to originate from somatic dysfunction of three main joints:

1) Pubic symphysis,

2) Sacroiliac joints, and

3) Lumbar vertebral segments.

Treadwell and Magnus in 1996 reported that sacral shears are a common disorder in the pregnant female due to the laxity of the ligaments.<sup>13</sup> In addition, they reported that a dysfunctional sacrum places undue stress on the surrounding musculature which can lead to multiple complications, such as low back pain, pelvic pain and can restrict fluid drainage through the pelvic diaphragm resulting in edema and venous insufficiency. They described a technique of placing the patient in the lateral recumbent position for diagnosis and treatment. The patient is placed shear side up with both legs flexed. The operator is positioned behind the patient and the caudal hand raises the patient's leg from the table and stabilizes the leg with the operator's elbow on the table. The cephalad hand is placed on the sheared ILA. The patient is asked to assist by compressing the elevated leg down and, while the sacroiliac joint opens, the operator springs through the inferior ILA. It is not uncommon for pregnant patients to have recurrent sacral shears. It has also been demonstrated that sacral rocking is effective in releasing sacral restrictions.<sup>7</sup> McIntyre and Broadhurst in 1996 demonstrated that a rotational mobilization technique was significantly effective in relieving low back pain in the pregnant female.<sup>8</sup> Seventy-five percent of the patients reported complete resolution after 3 treatments and the remaining 25 percent reported 50-80 percent resolution. Daly et al in 1991 also reported 91 percent resolution of low

back pain in patients demonstrating somatic dysfunction of the sacroiliac joint.<sup>2</sup> These investigations demonstrate two techniques that can be performed on the obstetric patient. They are effective in relieving low back pain that may be due to sacroiliac dysfunction.

Patients that exhibit low back pain primarily due to somatic dysfunction of the lumbar region can be treated with lumbar counterpressure, also known as inhibition. Guthrie and Martin in 1982 compared inhibition of the lumbar myalgia to the placebo effect during labor.<sup>5</sup> They applied counterpressure in the thoracic region to stimulate the "hands on" or placebo effect. They illustrated that lumbar inhibition relieved 81 percent of the back pain and that 88 percent of the patients needed less medication. Furthermore, lumbar inhibition reduced the use of major narcotics from 33.3 percent to 23 percent. The thoracic-treatment group collectively received 16 doses of narcotic while the lumbar-treatment group only received 3 doses. The pubes have also been effectively treated in the obstetric female by the use of pubic decompression and indirect techniques. It is also now apparent that there is a significant need to continue manipulative therapy into the post-partum period as many patients still demonstrate low back pain six months after delivery.<sup>7</sup> Even though there exist many manipulative techniques that are effective in relieving low back pain in the pregnant female, manipulative therapy is contraindicated during premature labor (it may enhance labor) and in the presence of placenta previa, abruptio placenta, premature rupture of the membranes and ectopic pregnancies.<sup>7</sup>

There are many preventive measures that the patient can perform at home which can assist in limiting the amount of back pain. The patient

*continued on page 36*



# Meniere's syndrome resulting from multiple traumatic brain injury: Two case studies

by Wesley C. Lockhart, DO, Department of Osteopathic Manipulative Medicine, Michigan State University College of Osteopathic Medicine

## Introduction

Two patients were referred to the Department of Osteopathic Manipulative Medicine at Michigan State University College of Osteopathic Medicine with a diagnosis of bilateral Meniere's disease. Both patients had undergone extensive medical testing. Neither had responded to conventional treatments for their episodic vertigo, nausea, tinnitus, aural pressure and hearing loss. We were consulted to determine whether there was a structural component contributing to the disease process. Both patients were found to have extensive histories of closed-head injuries. This resulted in the author making a subsequent diagnosis of Meniere's syndrome secondary to multiple traumatic head injuries. Both patients had additional neuromuscular dysfunctions that presented with significant biomechanical abnormalities. Primary treatment included manual manipulation of structural dysfunctions by the author aimed at improving the symptoms and decreasing the frequency of attacks experienced by the patients. After three months of treatment with a mean number of eight treatments, both patients had reported a decrease in episodes of severe vertigo with nausea and vomiting. One patient reported a reduction in vertigo with

head and neck rotation from constant to episodes of 5 to 7 times in a two to three week period; in addition, the vertigo was less intense during the episodes. This same patient experienced complete resolution of headache and neck pain for three weeks after the first treatment. Subsequently, when an episode of headache with neck pain did occur it was reported as less intense. Both patients were referred for neuro-ophthalmologic evaluation. One patient was referred for acupuncture. Osteopathic manipulation to reduce the structural dysfunction improved some of the symptoms and frequency but did not entirely resolve the symptoms of Meniere's syndrome.

## Hypothesis:

Multiple mild traumatic head injuries can lead to the development of Meniere's syndrome. This paper discusses the development of Meniere's syndrome as it relates to multiple traumatic brain injuries and offers a structural explanation using two patients as case studies.

## Background information:

Prosper Meniere,<sup>28</sup> in 1861, described a syndrome consisting of con-

tinuous or intermittent head noises accompanied by diminution of hearing, intermittent attacks of vertigo, dizziness, uncertain gait, staggering and falling accompanied by nausea, vomiting and syncope. In 1938, Hallpike and Cairns<sup>5</sup> and Yamakawa<sup>26</sup> independently reported the finding of endolymphatic hydrops in temporal bones from patients with Meniere's syndrome. Hallpike and Cairns emphasized the apparent idiopathic nature of the hydrops. For many years, investigators described the essential changes in the anatomy of the labyrinth thus making Meniere's a specific disease. In many patients vestibular or auditory symptoms can occur months or years prior to development of other symptoms. Only one fourth of the patients in a study by Paparella were found to have likely causes for Meniere's syndrome. These were infections; (i.e. otitis media, meningitis, viral inflammations), trauma (especially physical trauma or explosive sound), otosclerosis and syphilis. Paparella defined Meniere's "disease" as referring to the classic finding of episodic vertigo, fluctuating and progressive hearing loss, aural pressure and tinnitus, loudness intolerance and diplacusis due presum-

→



ably to its most important pathological correlate, idiopathic endolymphatic hydrops. Meniere's "syndrome" on the other hand is defined as having the same characteristic clinical features as Meniere's "disease" but occurring in a patient with an identifiable predisposing cause. The term "syndrome" is associated with a likely known cause for endolymphatic hydrops and cannot be termed idiopathic.<sup>14</sup> Etiologic factors noted by Rauch<sup>15</sup> contributing to the development of Meniere's syndrome are auto-immune reactions, allergic responses, blocked drainage, excess endolymph, autonomic imbalances, viral infections, dietary deficiencies and vascular irregularities. Ten percent of patients had a positive family history. Meniere's patients in general displayed hypocoelular mastoids on radiographs.<sup>24</sup> Endolymphatic hydrops is defined for the purpose of this paper as: hydrops present in any part of the membranous labyrinth which is responsible for the resorption of the endolymphatic fluid. Hydrops is described as an increase in the size of the sac with or without narrowing of the aqueductal valve.<sup>14</sup> The malabsorptive pathology has been widely described as a replacement of columnar epithelium with simple epithelium coinciding with loss of resorptive ability in the rugose portion of the endolymphatic sac, as well as, the cranial orifice portion.

## Case Histories:

### *Patient # 1:*

A 57 year old white male was referred to the Department of Osteopathic Manipulative Medicine at Michigan State University for structural evaluation related to dizziness for 15 years. Several specialists diagnosed him with bilateral Meniere's disease over the last six years. On initial examination the patient complained of constant roaring in his ears and feelings of loss of balance, espe-

cially when moving in a vehicle or when he turned his head. In addition, he had episodes of severe dizziness with nausea and vomiting that could strike any time and last from twenty minutes to as long as three days. These episodes occurred approximately every two to three weeks. His vision was occasionally compromised with blurring or a "gray cloud" over everything that he saw.

### *Past History:*

Significant for one closed head injury and one severe episode of acoustic trauma that the patient can remember. He related the beginning of his problems to an accident at the age of 24 when he dove into a pool and hit his head on the bottom. He was stunned for a few seconds with an additional feeling of numbness all over his body. Afterwards he felt nauseated and disoriented for 24 hours. The 'acoustic trauma' injury occurred several years before we first saw the patient. He relates that during an electrical storm, he arose from bed to close the curtains. A bolt of lightning struck outside the window approximately fifty yards away. The patient was knocked to the floor at which time he had severe dizziness with vomiting for six to seven hours. Once the vomiting stopped, he remained dizzy for three days. He has had episodic dizziness with nausea and occasional vomiting since that incident.

In addition, he states that he had several head injuries as a child growing up on the farm. He recalls one incident in which he was thrown from a horse. He relates other falls with mild head injury, but does not remember a distinct loss of consciousness. The patient also complained of recent onset of low back pain and discomfort radiating to the lower extremities.

Additional medical history includes hypertension, hypercholesterolemia and anxiety. The patient has had six angiograms over the last six years, four of which resulted in angioplasties. He

now has a stent in the left lower descending artery of the myocardium. Present Medications: diltiazem, long acting 240 mg per day, gemfibrozil 600mg per day, aspirin 325 per day

### *Listed review*

#### *of diagnostic testing:*

1. 24 Hour EEC - interpreted as normal
2. Auditory brain stem evoked response - abnormal with poor formation of wave 1 from the ears suggestive of a dysfunction between the inner ear and brain stem, bilaterally. From 1995
3. Visual evoked response - borderline abnormal, mild prolongation in the P100 latency from the left compared to the right eye. Suggestive of a dysfunction of the visual pathway for the right eye.
4. MRI with contrast - cerebral atrophy and a small vascular malformation (venous angioma) of the right cerebellar hemisphere. Minimal inflammatory changes of the paranasal sinuses. Internal auditory canals - similar in size and shape without evidence of intracanalicular or discrete cerebellopontine angle mass.
5. Color flow duplex sonography of the carotids - unremarkable
6. Conventional radiographs of the lumbar spine - minimal degenerative changes
7. MRI of the lumbar spine - minimal paracentral bulge at disc L2-3
8. Radionuclide bone scan - normal
9. Cervical spine study - normal
10. Auditory and visual evoked potentials from five years previous suggested no evidence of brain stem dysfunction. From 1990

### *Structural examination:*

Standing: The right acromion was



superior on the left. The right iliac crest and trochanteric heights were superior on the right. There was a positive forward bending test on the left, which was less with the arms extended over the head. (This represents myofascial stress from above the diaphragm affecting the sacroiliac joint.) Positive Gillet (stork) test on the right. There was decreased motion of the lumbar spine with side bending to the right. No scoliosis was noted.

**Seated:** Positive forward bending test was found on the right with arms extended over the head. This was negative with arms resting between legs. Trunk rotation was mildly decreased to the left.

**Supine:** A short medial malleolus was found on the left. Pubic symphysis was superior on the left. Pelvic muscle control for inferior pelvic tilt was restricted as well as rotation of the pelvis and lumbar spine to the left. The patient's attempt to achieve this position caused muscle spasm in the latissimus dorsi, quadratus lumborum and erector spinae on the right.

**Prone:** A short medial malleolus was found on the left. The left ilium was posteriorly rotated. The gluteus maximus was weak bilaterally. A dysfunctional paraspinal muscle-firing pattern for left leg extension was noted. The patient's firing pattern was: the hamstrings, erector spinae, contralateral quadratus lumborum, then ipsilateral quadratus for left leg extension rather than hamstrings, gluteus maximus, contralateral erector spinae and quadratus lumborum, then ipsilateral erector spinae and quadratus lumborum—which would be the preferred functional firing pattern which was present for extension of the right leg. In addition, the patient used latissimus dorsi and thoracic erector spinae to stabilize his back for extension of either lower extremity.

Sensorimotor balance testing on

one foot with arms down and eyes open revealed significant problems with balancing on the left. The patient would immediately fall to the right. He could stand on the right foot for more than five seconds with his arms down and eyes open without support.

Myofascial stresses were found at the occipitoatlantal junction and the suboccipital muscles on the right with splenius capitus and cervicis tight and restricted. The deep anterior cervical muscles on the right were inhibited and loose. The more superficial sternocleidomastoid, pectoralis minor and anterior scalene were tight and restricted. The latissimus dorsi were tight bilaterally (with the right being more restricted) which created an upper lumbar lordosis and significant lumbar extension. There was weakness of the serratus anterior as well as the rectus abdominus bilaterally. A right-on-right forward sacral torsion was accompanied with tight piriformis muscle, sacrotuberous and sacrospinous ligaments on the left. The hamstrings were tight and restricted bilaterally, left greater than right, as well.

Cranial evaluation revealed an increased cranial rhythmic impulse rate of 18 cycles per minute. The amplitude and vitality were decreased. A right sphenobasilar torsion, inferior vertical strain, left lateral strain and left side-bending pattern were found. The cranial pattern would easily change between the above patterns and was deemed unstable, as it appeared to be dependent on the respiratory (or secondary) rhythm. There was little to no independent movement of the sphenobasilar symphysis; this was highly suggestive of sphenobasilar compression.

#### *Treatment:*

##### First treatment

(one week after initial exam):

The patient was first treated by the author for low back pain and dysfunction, which was the most acute problem. A lower extremity EMG was re-

ported as normal from a neurologist consulted by the patient's family physician for the low back pain with some radiation down the right leg. The patient's back was treated with myofascial release and muscle energy technique for sacral restriction as well as thoracolumbar junction myofascial restriction, which included release of a very restricted right hemi-diaphragm. Individual segmental dysfunctions of the lumbar area were L5-ERS right with L4 following L5; the sacrum was still a right-on-right sacral torsion. All of these were treated with muscle energy. The overall cranial pattern was in extension with movement between a right torsion, inferior strain and a left lateral strain with left side-bending patterns.

##### Second treatment

(two weeks after first treatment):

Low back pain improved at least 50 percent by patient history. Vertigo continues, especially with any head movement. There is no improvement in the cranial rhythmic pattern; it continued to be an irregular, non-smooth movement, dependent on the breathing of the patient. Treatment aimed at sacral and thoracolumbar areas.

##### Third treatment

(three weeks after second treatment):

Patient stated that the Meniere's symptoms were not better. However, he had not had any episodes of severe vertigo with vomiting. Approximately one third of low back pain continues. Sacral restriction, thoracolumbar and diaphragmatic myofascial restrictions were again released with a direct myofascial release technique.

##### Fourth treatment

(three weeks after third treatment):

Consulted another osteopathic manipulative medicine specialist for acupuncture of the myofascial trigger points to aid in release of the

→



myofascial restrictions of the upper thoracic and cervicothoracic junction area which might have aided in release of the sphenobasilar compression. The patient received treatment for OA FRrS left with marked tissue tension abnormality, C2-3 rotated right, T 2,3,4 and 5 rotated left and sidebent right with HVLA by the consulting physician. Immediately following this treatment, treatment of the sphenobasilar compression was attempted using direct and indirect approaches to the barriers of motion, but was not released.

#### Fifth treatment

(one week after fourth treatment):

Patient felt his low back pain was improved. Cranial rhythmic impulse pattern established as low amplitude right torsion, left side bending. The patient continued to complain of intermittent low back pain, however he was working around the house and yard doing light to medium strenuous chores. He had not had an episode of severe dizziness and vomiting in three months, which was a significant improvement in frequency of attacks.

#### Sixth treatment

(one week after fifth treatment):

Patient states his Meniere's symptoms of vertigo and tinnitus are no better. The tinnitus is in fact a bit worse. Low back is 90 percent better by patient's admission. No episodes of severe nausea and vomiting. Cranial rhythmic impulse remains reduced in amplitude and irregular in a right torsion, left side-bending pattern. Treatment by the consulting osteopathic manipulative medicine specialist included dry needling of trigger points of the cervical, thoracic and lumbar regions. Immediately afterwards treatment by the author included myofascial release to the cervicothoracic junction, the thoracolumbar junction and to the sacrum. Indirect craniosacral therapy to the sphenobasilar symphysis was performed without release.

This was the last visit by the patient as he was attempting to obtain disability and would be referred to a Traumatic Brain Injury Rehabilitation Program near his home.

#### *Patient #2*

A 50-year-old white male patient was referred to the Department of Osteopathic Manipulative Medicine for a 6 year history of dizziness, hearing loss, buzzing in both ears, loss of balance and numbness in the right arm and fingers. His diagnosis was bilateral Meniere's disease. The patient could trace the beginning of the problem to when he was 28 years old. At that time, he was hit in the head with a hammer at work. Soon afterward he was evaluated for hearing loss and buzzing in his ears. There was no treatment at that time due to lack of physical evidence for the problem. In addition, he was able to relate another five incidents of closed head and/or neck injuries as a child, teenager and adult. Recall of his first head injury was at 5 years old when he was hit in the head with a large rock and required several stitches. He does not remember a loss of consciousness, but does remember being dazed. At 11 years of age he was rendered unconscious when someone dropped a cannon shell casing approximately 12 feet from a tree, hitting him on the top of the head. As a teenager, he was swinging on a rope and hit a support beam in a barn with full frontal body impact. He believes he was unconscious for several seconds.

The patient could relate at least three additional injuries that resulted in head and/or neck trauma as an adult. After the hammer strike to the head, in September of 1990, he fell out of a tree and landed on his back injuring his head, neck, and elbows. In addition, there was a snowmobile accident where he had a neck injury in which he could not move his neck for several days. He did not have a fracture, nor does he remember a spe-

cific head injury at that time. The patient also had an ice skating injury where he fell back hitting his head on the ice. He does not remember a specific loss of consciousness.

He continued to work at an assembly line job that required him to turn his neck from side to side often. This began to create severe dizziness and nausea in 1994. The patient relates a separate work related trauma approximately 3 years before the initial examination, when he injured his right arm while using a sledgehammer in the overhead position. The right shoulder and arm became weak and he complained of a tremor with any strenuous use or with the arm overhead. Only conservative treatment was given to the arm at the time of injury. However, he was diagnosed as having an ulnar nerve entrapment with carpal tunnel syndrome of the right upper extremity in June of 1995. He was evaluated for the Meniere's disease and the right upper extremity dysfunction by his family physician as well as referral to a neurologist, who subsequently referred him for evaluation, by a neuro-otologist. A review of the findings follow:

1. Mild right carpal tunnel syndrome due to ulnar entrapment at the elbow diagnosed with EMG by neurologist June 1995.
2. Vestibular function test by neuro-otologist revealed a compensated lesion of the labyrinth or vestibular nerve. A very strict vestibulo-ocular and vestibulo-spinal tract reflex exercise program was recommended. He was unable to tolerate the exercise program even with a mild vestibular depressant (meclizine hydrochloride).
3. MRI revealed a left maxillary polyp. There were no increased nor decreased signal intensities within the brain. Brain stem and cerebellum were normal.

*continued on page 37*



# Perspectives: An overview of support for osteopathy in the cranial field

by Michael L. Kuchera, DO, FAAO, Vice President and Dean,  
Kirksville College of Osteopathic Medicine

The osteopathic profession makes no exaggerated claims regarding either the use or the documentation of OMT in the head region. It balances its claims about its approach to "osteopathy in the cranial field" in its standard textbook, *Foundations for Osteopathic Medicine*, by saying:

*"Much research remains to demonstrate the exact mechanisms involved in craniosacral dysfunction and recovery. However, more than 50 years of clinical experience has indicated that the use of osteopathy in the cranial field has given relief to many patients in whom no other treatment was effective."<sup>1</sup>*

This short essay provides a quick overview of the diagnosis and treatment of somatic dysfunction in the head region, which is only one small component of osteopathy in the cranial field.

According to the Educational Council on Osteopathic Principles of the American Association of Colleges of Osteopathic Medicine,<sup>2</sup> all colleges of osteopathic medicine offer an overview of the principles and techniques of osteopathy in the cranial field. Mastery of physician-level treatment skills typically is reserved for post-graduate and/or continuing medical education. In osteopathy in the cra-

nial field and other physician models, it is important to recognize that diagnosis and treatment of somatic structures of the head region requires a skilled physician. Only a physician has the range of training and capabilities needed to differentiate functional symptoms from underlying pathology. Diagnostic and treatment regimens, which include appropriate follow-up and concomitant care (with or without medication), will also be discussed only from the physician-level model. This paper will not discuss so-called "craniosacral therapy" given by non-physician therapists with inadequate training.

## Somatic dysfunction of the head region

Somatic dysfunction is defined as impaired or altered function of the somatic system -skeletal, arthrodiagonal, and myofascial - and its related neural, vascular and Lymphatic elements.<sup>3</sup> The *International Classification of Diseases (ICD-9-CM)* further subdivides somatic dysfunction into regions, one of which is "somatic dysfunction - head region." Skeletal, arthrodiagonal, and myofascial structures in this region include (but are not limited to) the occipitoatlantal (OA) joint, the temporomandibular joint (TMJ), cranial sutural sites, and a number of muscles attaching to the cranium. Somatic dysfunction of

many of these structures has been correlated in numerous texts to dysfunction of related neural, vascular and Lymphatic structures related to the head region.<sup>4,5,6,7</sup> While osteopathy in the cranial field has much broader philosophical and clinical implications as practiced by osteopathic physicians, it specifically includes a number of manual techniques designed to modify or remove somatic dysfunction in the head region.

Somatic dysfunction in any region is based upon palpatory characteristics best summarized by the mnemonic, TART.<sup>8</sup> This mnemonic stands for Tenderness, Asymmetry, Restricted Motion, and Tissue Texture Abnormality. Other than "tenderness," which some feel may rely too heavily on the patient's subjective report, each component element has been well documented by basic and clinical scientists as being objective and reliable physical findings existing in every area of the body.<sup>9,10,11</sup> With respect to the head region, numerous researchers have documented both the existence of dysfunction (A, R, and/or T) in the head region and its clinical relevance. In the complete history and physical examination, an osteopathic structural examination of the entire body, including the head region, is required by the American Osteopathic Association for every hospitalized patient.<sup>12</sup>

→



**Asymmetry** of the head is frequently observed by parents, nurses and physicians to occur after birth with subsequent changes in shape occurring in the ensuing months. A diagnosis of somatic dysfunction of the head in which asymmetry is prominent may be alternatively referred to as plagiocephaly or as molding in a number of general medical texts. The finding of asymmetry of the head has a wide range of implications, some benign, some cosmetic, and some clinically relevant.<sup>13</sup> Pediatricians have documented an increase in the acquisition of post-natal cranial asymmetry as a result of recent recommendations for infants to sleep supine to reduce the incidence of Sudden Infant Death Syndrome. The title of their paper published in 1996 in *Pediatrics*, "Does supine sleeping cause asymmetric heads?"<sup>14</sup> Other correlations of asymmetry of the head and systemic complaints occur often in the literature. For example, the observation of a high arched palate combined with a narrow dental arch has been independently correlated with asthma and other recurrent upper respiratory symptoms by both dentists (*ref*) and osteopathic physicians.<sup>15,16</sup> This palate/dental arch shape is common in motion asymmetry referred to as extension type mechanics.<sup>17</sup> Motion testing of the TMJ with observable asymmetry as the jaw opens and closes is often recorded in the clinical documentation of temporomandibular joint (somatic) dysfunction and its treatment.<sup>18</sup> Static and dynamic asymmetry of facial musculature documented as ptosis, or as asymmetry of jaw clench, frown, or smile, are universally recognized to indicate dysfunction of myofascial (somatic) dysfunction and its related elements (usually neural). Asymmetry in the head region is therefore a universally recognized and valuable objective physical finding.

**Restricted motion** of somatic structures in the head region has also

been documented by a number of groups. Restriction of TMJ motion, for example, is clinically interpreted according to well-defined models of function and dysfunction pertinent to the practitioner's field of study - osteopathic medicine, specialty studies in ENT, dentistry, or chiropractic. Furthermore, the relevance of the articulations between the base of the skull and the cervical spine, their functions, and their vulnerability to trauma is well understood and well documented. Its importance is reflected in the large number of recent studies, which have been published concerning the OA articulation and its anatomic and functional relationships to a number of neural and vascular structures. Advances in technology have demonstrated previously undiscovered anatomic relationships<sup>19</sup> between musculature attaching to the base of the skull and to intracranial structures which offer new insights into post-traumatic cephalgia and other headaches.<sup>20,21</sup> Diagnosis and treatment of restricted motion and spasm in this area are used by any number of other practitioners, including doctors of osteopathic medicine with respect to tension cephalgia. Fewer professions have studied impaired or altered motion of cranial bone articulations (other than the occipitoatlantal joint and the temporomandibular joint) themselves. Within the osteopathic profession, restricted motion between cranial bones has been studied and documented by basic and clinical scientists. The recent series of animal model studies by S. Heisey, ScD and T. Adams, PhD has quantitatively demonstrated that cranial bones move relative to each other and that this movement contributes to a homeostatic mechanism, cranial compliance.<sup>22,23</sup>

For palpation in general, experts agree that individuals can perceive tissue movement as minute as 1 :m.<sup>24</sup> This (1-2 :m) was the range of motion between parietal bones in the cat

measured by Adams team in the previously mentioned study. Palpation of the human cranium and simulated models have been compared with several independent, objective, electronically-monitored motion parameters. These and other studies demonstrate the ability of osteopathic students and physicians to consistently palpate motion (amplitude and rate) using the "cranial vault hold,"<sup>25</sup> Measured on multiple occasions and in a variety of controlled environments - most recently by a series of researchers at the New York Institute of Technology - College of Osteopathic Medicine, interexaminer reliability has been shown to vary depending on the quality of motion tested, the experience of the examiners, the degree of pre-training to insure consistent testing methods, and whether the subject is neonatal or older.

Regardless of the actual source of the motion or its restriction, use of the cranial vault hold to document motion characteristics is considered valuable palpatory information to the clinician using the model described for osteopathy in the cranial field. Using this osteopathic model, clinicians document palpable restrictions of the amplitude, symmetry, and/or rate of motion in the head region. They record their findings of restricted motion as somatic dysfunction of the head region. These physicians add to an increasing body of knowledge by documenting motion characteristics of patients with various problems including psychiatric disorders, headaches, learning disorders, suckling disorders, and organ dysfunction including otitis media, and colic.<sup>26,27,28,29</sup> Thus, while the clinical relevance of restricted motion of some structures is well understood, other structures are now being actively studied in light of new technology capable of objectively quantifying the small changes in motion which occur. In any case, restricted motion of somatic structures in the



head region is an objective, codable palpatory finding considered valuable to a number of clinical models and patient conditions.

**Tissue texture changes** in the head region are commonly recorded as alteration of sweat gland activity, an autonomic function, or as muscle spasm or flaccidity. Often sites of tenderness are palpated for evidence of swelling, edema, warmth, spasm, or other descriptors of a tissue texture change. These findings have been correlated with traumatic, infectious, or malignant conditions or at least provide valuable information in the differential diagnosis of problems affecting the head. Janet Travell, MD and David Simons, MD dedicate a dozen chapters in their book, *Myofascial Pain and Dysfunction: The Trigger Point Manual (vol I)*,<sup>30</sup> to muscular (somatic) dysfunction associated with the head region. They describe in detail the palpatory tests and tissue texture characteristics defining latent and active myofascial triggerpoints used in this model of diagnosis and treatment. In addition to a number of well-documented headache pain patterns arising from muscles of the head region, they document, from clinical observation, associated symptoms affecting the function of the eyes, ears, nose, and throat and a number of cranial nerves. They also document impaired or altered Lymphatic, vascular and autonomic function secondary to these myofascial (somatic) changes. Tissue texture changes are also universally accepted objective physical findings best experienced through palpation.

In summary, a number of experts in a wide range of clinical and dental disciplines recognize that somatic dysfunction of head region structures plays a role in the diagnosis and/or treatment of multiple clinical entities. These entities present with a wide range of signs and symptoms including facial pain, organ dysfunction, muscle spasm, dizziness, visual dis-

turbances, disturbances of mastication, sinus symptomatology, and headache. Integrating objective findings of asymmetry, restricted motion and tissue texture change and interpreting them with different pathophysiologic models has resulted in a number of clinical-approaches. By definition, osteopathic physicians welcome Travell's-approach as a subset of their understanding of somatic dysfunction of the head region and as an additional set of treatment modalities to remove somatic dysfunction from the region.<sup>31</sup> The key is to record objective physical findings and integrate these findings into a clinical model which permits us to better understand pain and dysfunction in our patients. Osteopathic physicians using "osteopathy in the cranial field" as their operative model, look for visual and palpatory clues to somatic dysfunction (ART). This permits them to responsibly include primary and secondary "somatic dysfunction of the head region" in the differential diagnosis related to each presenting complaint.

## Treatment of somatic dysfunction of the head region

Barring certain well-described contraindications to specific techniques, a number of manipulative and physical modalities have been described to treat somatic dysfunction.<sup>32,33,34,35,36</sup> Most agree that the specific treatment technique is less important than the goal of reducing somatic dysfunction or otherwise restoring somatic functions. A number of mechanisms have been advanced to describe how these manipulative or physical maneuvers work, often postulating pathways whereby the treatment technique alters and reeducates the central response to peripheral receptor activity.<sup>37,38,39</sup>

Regardless of the postulated treatment mechanism or the pathophysi-

ologic model, from an outcomes perspective, treatment could be considered effective and the model considered to be operational if removal of somatic dysfunction results in the predicted modification or elimination of clinical signs and symptoms. For example, the osteopathic and myofascial triggerpoint models share a number of similarities as to diagnostic and treatment relevance but often differ in their postulated mechanisms. Each prescribes specific diagnostic and treatment actions and while many of these actions share common characteristics, many others are unique to the model upon which they are based. Each treatment claims a reduction in somatic dysfunction using the original diagnostic actions which, in turn, parallels reduction of patient signs and symptoms.

Travell's triggerpoint model documents myofascial somatic dysfunction as an important component of the differential diagnosis of head pain and disorders of the HEENT and it further documents that removal of this somatic dysfunction is an effective and important treatment approach. As previously mentioned, the osteopathic model also recognizes the importance of myofascial somatic dysfunction of the head region. This aspect is discussed in *Foundations of Osteopathic Medicine*<sup>40,41</sup> and in the HEENT chapter of *Osteopathic Considerations in Systemic Dysfunction*,<sup>42</sup> both frequently used teaching texts. Nonetheless, over and above myofascial somatic dysfunction, osteopathy in the cranial field also recognizes the skeletal and arthroal components of somatic dysfunction of the head region. In this regard, it may be important to note that some treatment to remove somatic dysfunction in the head region using an osteopathic model may be indistinguishable from techniques independently developed and described by Travell using the triggerpoint model.

→



This, even though the postulated mechanisms-of-action may differ. For example, treatment techniques independently described by Travell to alter autonomic activity to the nasal sinuses<sup>43</sup> or for improving eustachian tube function<sup>44</sup> are nearly identical to osteopathic cranial manipulation techniques postulated to affect the sphenopalatine ganglion.<sup>45</sup> In this case, the first treatments are based on the triggerpoint model while the other technique is based on the osteopathy in the cranial field model. Between different models, other treatment techniques to affect somatic dysfunction in the head region, including triggerpoint injections, pressure across sutural sites, and muscle stretching with or without vapocoolant spray, may share only partial similarity or may share none at all. The important fact to recognize is that effective treatments to remove somatic dysfunction vary as greatly as do models used to describe why they work.

### **Specific research related to osteopathy in the cranial field: Motion at the cranial sutures**

Reasoning from structure to function, William G. Sutherland, DO was struck by the articulations of a disarticulated skull mounted in Kirksville, Missouri. His description of craniosacral movement was espoused in 1939 after several years of careful observation, palpation, and experimental work with disarticulated bones. About Sutherland's contributions of thought, the osteopathic profession records, "One of the most innovative ideas to be advanced by a member of the osteopathic profession was the concept of articular mobility of the cranial bones ... His observations ... and discussions of diagnostic tests and treatment procedures for various conditions were presented in the book, *The Cranial Bowl*."<sup>46</sup>

Whether or not the cranial bones were capable of motion was an area

where dispelling dogma using experimental methods was important to the osteopathic community. Dispelling dogma is important to individuals on both sides of the issue. Nonetheless, proponents on each side of the question of cranial bone mobility were ready to argue dogmatically on the basis of "what was generally said or believed," rather than objectively looking at the data. At the root of this debate was the fact that Sutherland's observations and teachings led a number of osteopathic clinicians to diagnose and treat motion restrictions of the cranial sutures. Opponents dismissed this approach as quackery because most textbooks considered the cranium to be a rigid, relatively immovable container. If motion at the cranial sutures was not possible, then alternative postulated mechanisms for clinical success of certain cranial OMT Techniques would need to be developed.

To examine whether motion is possible at the sutures experimentally, the American Osteopathic Association, the American Academy of Osteopathy, and the Cranial Academy have all funded research. Additionally, a number of clinicians have independently studied interexaminer reliability of the palpatory components of somatic dysfunction of the head region and have recorded their clinical observations of components of the osteopathic model relative to the head region in various clinical and controlled settings.

Typical among these studies is the work of S. R. Heisey, ScD and Thomas Adams, PhD at Michigan State University. Their work<sup>47,48,49</sup> concludes that many of the original studies leading to the belief that the cranium is immovable were falsely influenced by the experimental use of an immobilizing frame. Modification of the method using strain gauges across the parietal suture in cats permitted documentation of motion measured as compliance (motion capabil-

ity). Furthermore, they demonstrated that in subjects with loss of cranial compliance (restricted cranial motion capability), there was a loss of the ability to compensate for increases in intracranial pressure. Dowling and Lewandowski at the New York Institute of Technology (NYIT) demonstrated a 95 percent correlation between physician observers palpating the cranial rhythmic impulse (a palpable component attributed to several elements of cranial motion) and a computer-based kinematic system making simultaneous measurements from reflective markers anchored by fine needles into the frontal and occipital bones of human subjects. These more recent studies from Michigan State University and NYIT build on earlier investigations of structure and function of the cranial sutures,<sup>50,51,52,53,54</sup> which sought to investigate the validity of Sutherland's observations and his hypotheses.

The implications of all of these findings may require a paradigm shift in the diagnosis and treatment of a number of conditions in which the cranial sutures are considered immovable. (As an aside, note that prior to 1960, the same dogmatic argument was ongoing on whether the sacroiliac joint was capable of motion. At that time, the American edition of *Gray's Anatomy* said there was no motion possible. Thus, despite clinical evidence to the contrary, osteopathic diagnosis and treatment of the sacroiliac joint was argued as obviously ineffective because textbook knowledge said that motion didn't exist in the first place. Now, international multidisciplinary conferences discuss the structure and function of the sacroiliac joint in detail along with its clinical relevance to pain and dysfunction.) In any case, experimental documentation should displace the dogmatic belief that the cranium is incapable of motion or the claims that attempts to remove somatic dysfunction of the head region are based on quackery or dogma.



## Specific research related to osteopathy in the cranial field: Clinical uses

The osteopathic profession has long been a service profession and admits that much clinical research must be performed in this area. Nonetheless, a wealth of clinical experience, a number of books, and increasing numbers of case reports published in the *Cranial Letter* and *AAO Journal* exist regarding the use of osteopathy in the cranial field as a clinical model for diagnosis and treatment of somatic dysfunction of the head region. Recently, these observations and increased funding to the AOA Bureau of Research have made increased research a possibility.

As an example, clinical observation empirically suggested a role for the use of osteopathic manipulative treatment in patients with otitis media.<sup>56</sup> This led to the design of several pilot studies at the osteopathic colleges in Missouri (Kirksville), Oklahoma, and West Virginia to examine the incidence and the relevance of somatic dysfunction of the head region in children with otitis media.<sup>57,58</sup> The relevance of somatic dysfunction of the cranium to pediatric patients with recurrent otitis media documented in these pilot studies led to two-year outcomes multicenter studies funded through the American Osteopathic Association's Bureau of Research. One was just completed and is being tabulated; the second was approved in July 1998.

The expert opinion of the profession regarding the clinical importance of the diagnosis and treatment of somatic dysfunction of the head region in a variety of musculoskeletal and systemic disorders is expressed in several peer-reviewed texts. These texts include, *Foundations for Osteopathic Medicine*, published as an AOA-endorsed consensus text by Williams & Wilkins (1997), and *An*

*Osteopathic Approach to Diagnosis and Treatment*, published in its second edition by J. B Lippincott (1997). Consensus also appears in numerous textbooks written by acknowledged leaders in the specialty field of Osteopathic Manipulative Medicine. Consensus in teaching the role of diagnosis and treatment of somatic dysfunction of the head region is also actively sought by educational subcommittees of both the American Academy of Osteopathy and the Educational Council on Osteopathic Principles of the American Association of Colleges of Osteopathic Medicine. As a consequence of ongoing research and dialogue, predoctoral, postdoctoral and continuing medical education (CME) concerning osteopathy in the cranial field is continuously updated and offered throughout the United States.

As a profession, we are aware of our clinical strengths and of the need for a stronger research agenda. Nonetheless, professional expert opinions, expert consensus and peer-reviewed texts are strong starting points for our ever-increasing research agenda. In closing this perspective, the June 1992 editorial by Michael M. Patterson, PhD in the *Journal of the American Osteopathic Associations*, is relevant and worth repeating.

"...The September 1991 issue of the *JAOA* ... featured an editorial calling for more theory building and for the testing of osteopathic medical tenets with scientific investigations, both basic and clinical.

Good, scientifically valid and well-designed studies are, perhaps, one of the most difficult things a practicing physician can undertake in the office setting.... This type of undertaking, however, is the ultimate testing ground for the ideas and theories of the profession.

The basic scientist can present mechanisms that may underlie the clinical phenomena observed in the office setting. Our educational institu-

tions can support complex studies, requiring major investments of resources and manpower.

Furthermore, we can borrow data from other professions to explain those observations and clinical successes of the osteopathic medical profession. However, one of the best ways to show the efficacy of osteopathic medicine is to study the phenomena in its natural setting, the office practice.

Viola M. Frymann, DO and her colleagues, Richard E. Carney, PhD, and Peter Springall, PhD, did just that. ...these researchers present the results of a very energetic undertaking conducted at the Osteopathic Center for Children in La Jolla, California. They designed and carried out a prospective study<sup>60</sup> examining the effects of osteopathic medical care on children with neurologic developmental problems. This study, conducted during a 3-year period, represents a massive, concerted effort to test the osteopathic medical profession's claims that it offers treatment and care for a broad range of human problems, not just back problems.

The researchers evaluated 186 children, aged 18 months to 12 years, as they underwent osteopathic manipulative treatment (OMT) for neurologic, medical, or structural disorders. The data show that OMT had positive effects on the levels of neurologic development in children with neurologic deficits. These beneficial effects continued long after treatment stopped.

Immense effort went into the design, execution, analysis, and pre-publication preparation of this study. It should be a landmark event for the osteopathic medical profession because it shows that such studies are feasible; they can be accomplished. Of course, the fact that OMT seems to have "worked," just as many of us in the osteopathic medical profession would have predicted, makes this a landmark study. A starting point that should not be taken lightly, this study should pave the way for more studies in the office setting.

It is the office setting, after all, that will serve as the ultimate testing ground for osteopathic medical phi-



osophies, thereby completing the circle from clinical observation to final clinical test."

Osteopathy in the cranial field developed from applying osteopathic principles to the study of the functional anatomy of the cranium. From empirical observations to multicenter clinical research, osteopathic practitioners have continuously sought to better understand the local and systemic effects of somatic dysfunction of the head region and outcomes of correcting that dysfunction. Properly integrated into a physician's complete evaluation of the patient, this model of osteopathic diagnosis and treatment offers documented beneficial options for primary or adjunctive care in enhancing health or treating disease and dysfunction.

## References:

1. Ward RC (Ed): Foundations for Osteopathic Medicine. Baltimore MD, Williams & Wilkins, 1997, p.913.
2. Kuchera M: 1998 Annual Report of the Educational Council on Osteopathic Principle to AACOM.
3. Educational Council on Osteopathic Principles (Ed): Glossary of Osteopathic Terminology in Ward RC (Ed): Foundations for Osteopathic Medicine. Baltimore MD, Williams & Wilkins, 1997, p. 1 138.
4. Travell JG, Simons DG: Myofascial Pain and Dysfunction, The Trigger Point Manual. Baltimore MD, Williams & Wilkins, 1983.
5. Magoun HI: Osteopathy in the Cranial Field (3<sup>rd</sup> edition). Kirksville MO, The Journal Printing Co, 1976.
6. Kuchera ML, Kuchera WA: Osteopathic Considerations in Systemic Dysfunction (2<sup>nd</sup> edition revised). Columbus OH, Greyden Press, 1994.
7. Ward RC (Ed): Foundations for Osteopathic Medicine. Baltimore MD, Williams & Wilkins, 1997.
8. Kappler RE: Chapter 39. Palpatory skills, an introduction. In Ward RC (Ed): Foundations for Osteopathic Medicine. Baltimore MD, Williams & Wilkins, 1997, pp. 473-477.
9. Heath DM: Chapter 77. Somatic dysfunction, effects of manipulative treatment and impact on health status. In Ward RC (Ed): Foundations for Osteopathic Medicine. Baltimore MD, Williams & Wilkins, 1997, pp. 1067-1075.
10. Peterson B (Ed): The Collected Papers of Irvin M. Korr. Newark OH: American Academy of Osteopathy; 1997.
11. Beal MC, Goodridge JP, Johnston WL, et al: Interexaminer agreement on patient improvement after negotiated selection of tests. JAOA. 1979; 79:432-440.
12. American Osteopathic Association: The Accreditation Requirements for Health Care Facilities. Chicago IL: American Osteopathic Association, 1998.
13. Lay EM: Chapter 64. Cranial field. In Ward RC (Ed): Foundations for Osteopathic Medicine. Baltimore MD, Williams & Wilkins, 1997, pp. 901-913.
14. Hunt, CE, Peczynski MS: Does supine sleeping cause asymmetric heads?" Pediatrics 1996; 98: 127-129.
15. Magoun HI: Osteopathy in the Cranial Field 3<sup>rd</sup> edition Kirksville MO: Journal Printing Co; 1976, p. 268.
16. Kuchera ML, Kuchera WA: Osteopathic Considerations in Systemic Dysfunction (2<sup>nd</sup> edition revised). Columbus OH, Greyden Press, 1994, pp. 48-49.
17. Magoun HI: Osteopathy in the Cranial Field 3<sup>rd</sup> edition Kirksville MO: Journal Printing Co; 1976.
18. Lay EM. In Gelb H (Ed): Clinical Management of Head, Neck and TMJ Pain and Dysfunction. Philadelphia PA, WB Saunders Co, pp 17-, 1977.
19. Hack GD, Koritzer RT, Robinson WL, Hallgren RC, Greenman PE: Anatomical relationship between the rectus capitis posterior minor muscle and the dura mater. Spine 1995, 20:2484-2486.
20. Hallgren RC, Greenman PE, Rechten JJ: Atrophy of suboccipital muscles in patients with chronic pain: a pilot study. MOA 1994; 94:1032-1038.
21. Hallgren RC, Hack GD, Lipton JA: Clinical implications of a cervical myodural bridge. AAO Journ 1997; 7(4):30-34.
22. Adams T, Heisey SR, Smith MC, Briner BJ: Parietal bone mobility in the anesthetized cat. JAOA, 1992, 92:599-622.
23. Heisey SR, Adams T: Role of cranial bone mobility in cranial compliance. Neurosurgery, 1993, 33:869-877.
24. Greenman P: Principles of Manual Medicine. Baltimore MD, Williams & Wilkins, 1989.
25. Kappler RL, Ramey KA: Chapter 44. Head, diagnosis and treatment. In Ward RC (Ed): Foundations for Osteopathic Medicine. Baltimore MD, Williams & Wilkins, 1997, p. 539.
26. Woods JM, Woods RH: A physical finding related to psychiatric disorders. JAOA 1961, 60:988-993.
27. Frymann VM: Relation of disturbances of craniosacral mechanism to symptomatology of the newborn: study of 1,250 infants. JAOA 1966; 65:1059-1075.
28. Frymann VM: Learning difficulties of children viewed in light of the osteopathic concept. JAOA 1976; 76:46-61.
29. Frymann VM, Carney RE, Springall P: Effect of osteopathic medical management on neurologic development in children. JAOA 1992; 92(6):729-744.
30. Travell IG, Simons DG: Myofascial Pain and Dysfunction, The Trigger Point Manual. Baltimore MD, Williams & Wilkins, 1983, pp.165-32931. Kuchera ML: Chapter 66. Travell and Simons' myofascial trigger points. In Ward RC (Ed): Foundations for Osteopathic Medicine. Baltimore MD, Williams & Wilkins, 1997, pp. 919-933.
32. Ward RC (Ed): Foundations for Osteopathic Medicine. Baltimore MD, Williams & Wilkins, 1997.
33. DiGiovanna EL, Schiowitz S: Osteopathic Approach to Diagnosis and Treatment (2<sup>nd</sup> edition). Philadelphia PA, JB Lippincott, 1997.
34. Magoun HI: Osteopathy in the Cranial Field 3<sup>rd</sup> ed. Kirksville MO: Journal Printing Co; 1976, p. 268.
35. Travell JG, Simons DG: Myofascial Pain and Dysfunction, The Trigger Point manual Baltimore MD, Williams & Wilkins, 1983.
36. Kimberly PE (Ed): Outline of Osteopathic Manipulative Procedures (3<sup>rd</sup> edition). Kirksville MO, KCOM Press, 1980.
37. Travell JG, Simons DG: Myofascial Pain and Dysfunction, The Trigger Point Manual. Baltimore MD, Williams & Wilkins, 1983, pp. 63-99.
38. Korr IM (Ed): The Neurobiological Mechanisms in Manipulative Therapy. New York NY: Plenum Press; 1978.
39. Korr IM: Proprioceptors and somatic dysfunction JAOA 1976; 74:638-650.
40. Kappler RE, Ramey KA: Chapter 44. Head, diagnosis and treatment. In Ward RC (Ed): Foundations for Osteopathic Medicine. Baltimore MD, Williams & Wilkins, 1997, pp. 515-540.
41. Kuchera ML: Chapter 66. Travell and Simons' myofascial trigger points. In Ward RC (Ed): Foundations for Osteopathic Medicine. Baltimore MD, Williams & Wilkins, 1997, pp. 919-933.
42. Kuchera ML, Kuchera WA: Osteopathic Considerations in Systemic Dysfunction (2<sup>nd</sup> edition revised). Columbus OH, Greyden Press, 1994, pp. 1-22.
43. Travell JG, Simons DG: Myofascial Pain and Dysfunction, The Trigger Point manual Baltimore MD, Williams & Wilkins, 1983, pp. 260-272.
44. Travell JG, Simons DG: Myofascial Pain



- and Dysfunction, The Trigger Point Manual. Baltimore MD, Williams & Wilkins, 1983, pp.249-259.
45. Magoun HI: Osteopathy in the Cranial Field 3rd ed. Kirksville MO: The Journal Printing Co; 1976; p.183.
  46. Northup GW (Ed): Osteopathic Research: Growth and Development. Chicago IL: American Osteopathic Association; 1987, p. 40.
  47. Heisey SR, Adams T: Role of cranial bone mobility in cranial compliance. Neurosurgery 33:869-877, 1993.
  48. Adams T, Heisey SR, Smith MC, Briner BJ: Parietal bone mobility in the anesthetized cat. JAOA 92:599-622, 1992.
  49. Heisey SR, Adams T, Smith MC, Briner B: The role of cranial suture compliance in defining intracranial pressure. MOA 93(9)951, 1993.
  50. St. Pierre NF, Stedman P, Glick P: The detection of relative movements of cranial bones. JAOA 1976; 76:289.
  51. Frymann VM: A study of the rhythmic motions of the living cranium. MOA 1971; 70:928-945.
  52. Michael DK, Retzlaff EW: A preliminary study of cranial bone movements in the squirrel monkey. JAOA 1975; 866-869.
  53. Retzlaff EW, Michael DK, Roppel R, Mitchell F: The structures of cranial bone sutures. JAOA 1976; 75:607-608.
  54. Retzlaff EW, Mitchell FL, Upledger JE, Biggert T: Nerve fibers and endings in cranial bone sutures. JAOA 1978; 77:474-475.
  55. Frymann VM: Diagnosis and treatment of otitis media in children (1992). In King HH (Ed): The Collected Papers of Viola Frymann, DO: Legacy of Osteopathy to Children. Indianapolis IN: American Academy of Osteopathy; 1998, pp. 110-111.
  56. Block MA: Texas DOs learn to treat otitis media with OMT. The DO July 1993, pp. 44-46.
  57. Degenhardt BF, Kuchera ML: The prevalence of cranial dysfunction in children with history of otitis media from kindergarten to 3rd grade. JAOA 1994; 94:754.
  58. Degenhardt BF, Kuchera ML: The efficacy of osteopathic evaluation and manipulative treatment in reducing the morbidity of otitis media in children MOA 1994; 94:673
  59. Patterson MM: Testing osteopathic medical concepts in a real-life setting. MOA 1992; 92:689.
  60. Frymann VM, Carney RE, Springall P: Effect of osteopathic medical management on neurologic development in children. JAOA 1992; 92(6):729-744. □

## AAO's Bookstore adds (3) Books



### **Osteopathic Principles in Practice, Revised Second Edition**

by William A. Kuchera, DO, FAAO and Michael A. Kuchera, DO, FAAO

*"Learning to be an osteopathic physician is a cooperative venture between the student and the faculty. There is no way that the faculty, through lecture and demonstration, can give the student all the information that will be needed as a physician. The student must have or develop a driving desire to learn, to know, to read about and to practice the basic osteopathic philosophy, principles, techniques, and procedures presented during the training years. This text is designed and presented with the expectation that each student will graduate as a sensitive, well-trained physician who puts their osteopathic principles into practice*

- \* providing the latest indicated text, pharmaceutical and surgical aids,
- \* recognizing the fact that even though illness today may be caused by stress, disease, and accident, clues to dysfunction in the body will be found in the neuromusculoskeletal system;
- \* designing treatment to maximize structure-function relationships and homeostatic responses with the body unit."

### **Easy OMT:**

#### **An easy to use, step-by-step photo reference guide to manual medical care**

by William H. Howard, DO

Retired Kirksville College of Osteopathic Medicine Professor William L. Kuchera, DO, FAAO writes in the foreword:

*"Easy OMT presents the basic HVLA, muscle energy, and indirect osteopathic manipulative techniques following the outline of the Kimberly Manual of Manipulation as taught in the osteopathic medical colleges in the United States.*

*"The presentations are concise and clear. The professional photos orchestrated by Dr. Howard clearly illustrate the position of the patient, the position of the physician and intent of the technique. . .*

*"It is my recommendation that this new edition be in the reference library of every osteopathic medical student and physician."*

### **Osteopathic Considerations in Systemic Dysfunction**

by M. L. Kuchera, DO, FAAO and W. A. Kuchera, DO, FAAO

*This text encourages the reader to examine familiar medical facts, anatomic relationships and physiologic functions from the osteopathic perspective. This perspective can then be carried into the diagnostic and therapeutic decisions which will repeatedly be required of the medical student and the osteopathic physician for the rest of their professional lives.*

*This text does not propose to replace the many reference texts of medicine and does not include a complete differential diagnosis or a complete treatment plan for the clinical situations that are discussed. Its purpose is to explore selected structural and functional considerations which may produce symptoms or compromise homeostasis. It also demonstrates, by example, clinical application of the osteopathic philosophy in selected situations. Lastly, it attempts to show where osteopathic manipulative treatments can be prescribed as primary or adjunctive modalities available to the physician as they assist patients in reaching their maximum health potential.*



# A review of the principles of William G. Sutherland's general techniques

by William J. Golden, DO, Department of Osteopathic Manipulative Medicine, Michigan State University College of Osteopathic Medicine

*The following paper is the result of the author's opportunity to personally interact with several osteopathic clinicians that were students of Dr. William Sutherland. After observing a diversity of techniques amongst them, an endeavor to discover a common method of approach was pursued. This paper is not only a reflection of those experiences but also of the writings of others (the majority being students of Sutherland's) in the attempt to bring together and harmonize the osteopathic principles taught by Dr. Sutherland.*

## Introduction

Dr. Sutherland's approach to the treatment of areas other than the cranium are referred to as "general techniques." These treatment modalities were early applications of an indirect method in manipulative management to establish what he expressed as a state of "balance" in the function of tissues (bony and soft). In his general manipulative procedures, Sutherland's hand placements, patient positioning, etc., have already been described.<sup>1,2</sup> Several approaches using variations of these procedures have also been reported.<sup>3,4,5</sup> This paper instead will explore some of the basic osteopathic principles and methods that involve a variety of concepts underlying these procedures.

## Historical background

H.A. Lippincott, DO was a devoted student of Sutherland's, studying his philosophy and describing his techniques.<sup>6,7</sup> In 1949, he writes: "In these days of rapid changes in medicine, older methods are constantly being replaced by new, and there is a scoffing at the procedures that were used in the days of our grandfathers."<sup>6</sup> Let us therefore neither scoff nor ignore these foundations but rather learn from them by examining their underlying principles. In another article of Lippincott's he states: "It is evident that Dr. Still treated his patients carefully, with due consideration for the delicacy and the welfare of the tissues beneath his fingers. It is also evident that he imparted to the students who came under his supervision this wholesome respect for the tissues, the structures, and their functioning."<sup>7</sup> One of those students of Dr. Still's was William Garner Sutherland who graduated from the American School of Osteopathy at Kirksville, Missouri in 1899.

Dr. Sutherland referred to strains that involve the bony cranium and its dural membrane as membranous articular strains, and to those that involve joints outside the cranium surrounded by ligaments as ligamentous articular strains. The osteopathic technique of William G. Sutherland, DO is sometimes referred to as balanced

ligamentous release, or ligamentous articular release. "The purpose of the technique is to establish a state of ligamentous balance by placing the joint in the position which puts just enough tension on the weakened ligaments to balance the tone in the unstrained tissues. This position is commonly found in the direction into which the joint moves most freely. When it is found and it is established, it is maintained by the hold of the operator."<sup>8</sup>

Ligamentous articular strain (or balanced ligamentous tension) techniques are used to treat dysfunction at lesioned segments. Historically termed the osteopathic lesion, these dysfunctions were described as "strains of the tissue of the body."<sup>9</sup> Strain, as defined in the Glossary of Osteopathic terminology, is a "distortion with deformation of tissue" evident by the presence of "motion and/or positional asymmetry associated with elastic deformation of connective tissue (fascia, ligament, membrane)."<sup>10</sup> This distortion can be induced by physical trauma (either micro or macro), reflexes (such as visceral), emotional trauma, and perhaps by external forces in utero and during the birth process.<sup>11</sup>

Thomas F. Schooley, DO has summarized Dr. Sutherland's approach to general techniques as follows: "The principle of 'indirect action' tech-



nique is to position the articulation in such a manner that there is no tension on any of the periarticular tissues in any of the cardinal planes of motion. This position has been called... 'balanced ligamentous tension.' It is this position, with all tension removed, that will allow edematous fluids to escape into the surrounding tissues and circulatory system ...when the edema has been eliminated and muscles relaxed, *the body's own healing forces* will restore the periarticular tissues to their normal state of health. This healing mechanism is known as homeostasis."<sup>12</sup>

## Osteopathic principles

### *The Natural Healing Power*

The principle involved in "body's own healing forces" is critical to the understanding of Dr. Sutherland's teachings and methods. Osteopathy is an art and science based on an articulated philosophy; the inherent ability of self-regulation, self-healing, and self-maintenance appears to be a cornerstone in that foundation. Termed *vis medicatrix naturae* in Latin, or "Breath of Life" by Dr. Sutherland, the "inherent recuperative, restorative, and rehabilitative power...(is evident when) we recover from illnesses, fevers drop, blood clots and wounds heal, broken bones unite, infections are overcome, skin eruptions clear up, and even cancers are known to occasionally undergo 'spontaneous remission.'"<sup>13</sup>

It is this "body's own healing forces" that Edna Lay, DO comments on as the "use (of) the power or potency of the inherent activity of the primary respiratory mechanism (PRM) within the patient to assist the release of strains."<sup>14</sup> The PRM is described as having five anatomic-physiologic components: 1) the inherent motility of the brain and spinal cord, 2) fluctuation of the cerebrospinal fluid, 3) mobility of intracranial and intraspinal membranes, 4) articular mobility of cranial bones, and 5)

the involuntary mobility of the sacrum between the ilia.

Rollin E Becker, DO states: "Health requires that the PRM have the capacity to be (an) involuntary, rhythmic, automatic, shifting suspension mechanism for the intricate, integrated, dynamic interrelationships of its five elements. It is intimately related to the rest of body *through its fascial connections* from the base of the skull through the cervical, thoracic, abdominal, pelvic, and appendicular areas of the body physiology. Since all the involuntary and voluntary systems of the body, including the musculoskeletal system, are found in *fascial envelopes*, they too, are subject to the 10 to 14 cycle-per-minute rhythm of the craniosacral mechanism in addition to their own rhythms of involuntary and voluntary activity."<sup>15</sup>

### *Body Unity*

Fascia is a Latin word that means a "band." It is a sheet of continuous fibrous tissue that lies deep to the skin and invests all the structures of the body. Another concept of Dr. Sutherland's general technique, which also incorporates the osteopathic philosophy, is the unity of the person. "Anatomically, all the body structures are involved in connective tissue or fascia, making them continuous and mechanically interdependent... when one component is stressed or altered, other components are affected and respond accordingly."<sup>16</sup> As the body is united anatomically, that which makes the body mechanically continuous, as a unified system is the fascia. Fascia "surrounds each muscle, vein, nerve, and all organs of the body."<sup>17</sup>

"From a functional point of view, the body fascia may be regarded as a single and continuous laminated sheet of connective tissue. This laminated sheet extends without interruption from the top of the head to the tips of the toes. It contains pockets, which allow for the presence of the viscera, the visceral cavities, the muscle and skeletal struc-

tures. It also contains concentrically placed tubes which allow for the passage of central nervous system, the vertebral column and related structures."<sup>18</sup>

"Fascia is very extensive. If all other tissues and organs were removed from the body, with the fascia kept intact, one would still have a replica of human anatomy. Fascia surrounds every muscle and compartmentalizes organs in the face, neck, and mediastinum. Fascia forms sheaths around nerves and vessels. It envelops the thoracic and abdomino-pelvic organs. Fascia connects bone to bone, and forms tendinous bands and pulleys."<sup>19</sup>

Thus, these two key principles of osteopathic philosophy, the unity of the body and the natural healing force, (reflected as the "inherent activity of the PRM,") are common to the methods of Dr. Sutherland. There are two other important principles of osteopathic philosophy that get frequent reference: structure and function are reciprocally interrelated; and rational therapy is based on body unity, self-regulation, and the interrelationship of structure and function.

## Application of principles

Thomas F. Schooley offers some comments about the therapeutic procedures that Dr. Sutherland applied in addressing these principles: "He taught his students to first determine the direction in which the somatic dysfunction was produced. This is the direction of greater motion. He taught us to move the articulation in this direction to the limit of available range of motion and then to 'back off' or release the motion very slightly to the point where there was no tension on the supporting ligaments in any of the three cardinal planes of motion and then to hold the articulation at this point until there appeared a softening or relaxation of the periarticular tissues... the operator actually moves the articulation *in the direction in which the somatic dysfunction was produced.*"<sup>20</sup> The under-

→



lying concept that many of the Sutherland students seemed to agree upon, was that maintaining this "position of balanced tension" allows the inherent force, the self-healing *vis medicatrix naturae* to work.<sup>21</sup> Edna Lay, DO writes: "keep your sensing apparatus alert so that it perceives the slow movement of the PRM (primary respiratory mechanism). This movement feels like a longitudinal ebb and flow or a subtle pumping effect up and down the spine...continue to maintain this positioning and to observe this rhythmic motion; the inherent force is working through the tissues that are maintaining the somatic dysfunction. As they accomplish their task for this articulation at this time, the amplitude of the inherent rhythm lessens and the pumping decreases, and the tissues beneath your palpating fingers seem to soften or melt."<sup>22</sup>

## Discussion

Presented in this paper are some basic, common underlying principles that were utilized by several students of Dr. William Sutherland. Continuing development of such principles as body unity, the self-healing capabilities of the body, and therapy based on these concepts were carried on by several of Dr. Sutherland's students (Drs. R. Becker, E Lay, T. Schooley, A. Wales, and Herbert Miller respectively).

Key application was the use of indirect methods to treat somatic dysfunctions. Procedures "that initiate directions of decreasing tissue resistance are termed indirect."<sup>23</sup> Application of the indirect method used by several Sutherland students applied terminology to express a concept of "retracing the path of the lesion."

The indirect method of decreasing tissue tension is not isolated to Sutherland's general techniques. By 1964, Lawrence Jones, DO who introduced "Spontaneous Release by Positioning" writes: "even the severest lesion will readily tolerate being returned to the position in which the formation

originally occurred, and only this position. When the joint is returned to this position, the muscles promptly and *gratefully* relax."<sup>24</sup>

Also, the positional terminology and concepts such as "retracing the path of the lesion" are not a universal medium for describing the application of indirect methods. One needs to consider the functional orientation for technic in its development by Drs. Hoover, Bowles, and Johnston beginning in the 1940s. "Functional" technique is also considered an indirect manipulative method. Instead of retracing the path of the lesion and reiterating other positional concepts, their orientation embodied a concept "of a mobile system and mobile segments that acted in concert with one another."<sup>25</sup> It is not a positional criteria that is applied in functional; rather, it is the palpable response to specific motion demands. There is a motor coordination "necessary for each bone to be in the right place at the right time during these demands, implying a theoretic basis in neurophysiology for indirect methods."<sup>26</sup>

The osteopathic principles underlying the methods and concepts of Dr. Sutherland's general techniques, such as body unity and the self-regulatory, self-healing, and self-maintenance of the body, continued being reflected in the writings of his students. Using indirect methods in manipulative treatment for somatic dysfunction also continued to be a frequent approach amongst his students. However, the concept of position or retracting the "position in which the lesion occurred" may deserve reconsideration as a teaching tool for indirect method, in light of the diverse themes that have emerged.

## Bibliography

1. Lippincott HA; The Osteopathic Technique of Wm G. Sutherland, DO Academy of Applied Osteopathy 1964 Yearbook, p 138-146.
2. Sutherland Wm G.; Teachings in the Sci-

- ence of Osteopathy. Sutherland Cranial Teaching Foundation 1990, p 191 -217.
3. Miller Herbert, DO, FAAO; personal communication.
4. Becker Rollin; Diagnostic Touch Part III Academy of Applied Osteopathy Yearbook, 1964, p 161166.
5. Chila Anthony; Fascial-Ligamentous Release. Foundations for Osteopathic Medicine. Williams and Wilkins, 1997, p 819-832.
6. Lippincott HA; The Osteopathic Technique of Wm G. Sutherland, DO, American Academy of Osteopathy Yearbook, 1964, p 138.
7. Lippincott HA; Basic Principles of Osteopathic Technic; AAO Yearbook, 1961, p 45.
8. Wales Anne; Ligamentous Articular Strains and Membranous Articular Strains American Academy of Osteopathy Yearbook, 1951, p 74.
9. Lippincott HA; American Academy of Osteopathy Yearbook, 1964, p 138.
10. The Glossary Review Committee of the Educational Council on Osteopathic Principles. Glossary of Osteopathic Terminology, AOA, 1993.
11. Lay Edna; An Outline of Osteopathy in the Cranial Field. Department of Osteopathic Theory and Methods, 1980, p 1.
12. Schooley T; Osteopathic Principles and Practice, 1987, p 45.
13. Korr I; An Explanation of Osteopathic Principles. Foundations for Osteopathic Medicine. Williams and Wilkins, 1997, p 10.
14. Lay E; Cranial Field. Ibid. p 911.
15. Becker Rollin; Craniosacral trauma in the adult. Osteopathic Annual, 1976, 4:43-59.
16. Seffinger M; Osteopathic Philosophy. Foundations for Osteopathic Medicine. Williams and Wilkins, 1997, p 4.
17. Still AT; The Philosophy and Mechanical Principles, p 60.
18. Upledger J; Craniosacral Therapy. Eastland Press, 1983, p 237-238.
19. Burns N; Fascia. An Osteopathic Approach to Diagnosis and Treatment. Lippincott-Raven, 1997, p 19
20. Schooley T; Osteopathic Principles and Practice. Privately published, 1987, p 44.
21. Lay Edna; Cranial Field. Foundations for Osteopathic Medicine, p 912.
22. Ibid. p 912.
23. Johnston Wm, Friedman H; Functional Methods. American Academy of Osteopathy, Indianapolis, Indiana, 1994.
24. Jones, L; Spontaneous release by positioning. The DO, 1964, 4: 109- 116.
25. Foundations, p 800.
26. Johnston, Wm, DO, FAAO; Personal communication. □




# "An Introduction to OMT"

(Basic High Velocity/Low Amplitude)

January 20 - 23, 2000

CME Hours:  
23 Category 1A



**Sanibel Harbour  
Resort & Spa**



Sanibel Harbour is nestled on 80 acres of a private peninsula in Fort Myers, Florida, overlooking Sanibel and Captiva islands, approximately 25 minutes from the Southwest Florida International Airport. It boasts of 320 hotel rooms, suites, and condominiums.

## Resort Amenities:

- 1/2 mile jogging/nature trail
- Boardwalk through mangrove forest
- Babysitting services
- Kids' Klub (ages 5-12)
- Free shuttle to Sanibel
- Free shuttle to outlet mall
- 1,000 ft. sandy beach

## Program

### Thursday, January 20, 2000

- 5:00 pm Registration Opens (incl. evening meal)
- 5:30 pm Introduction to Course
- 5:45 pm History/Philosophy of Osteopathy
- 7:30 pm Introduction to OMT
- 8:00 pm Osteopathic Terminology,  
Palpatory Diagnostic  
Parameters, Barrier Concept
- 8:45 pm Principles of HVLA Technique
- 9:15 pm SUMMARY
- 9:30 pm Adjourn

### Friday, January 21, 2000

- 7:00 am Spinal Biomechanics
- 8:00 am Pelvis Diagnosis & Treatment
- 10:45 am Small Group Discussion
- 11:00 am Lumbar Spine Dx/Tx
- 1:30 pm Adjourn

### Saturday, January 22, 2000

- 7:00 am Pathophysiologic Models
- 8:00 am Thorax Dx/Tx
- 10:30 am Small Group Discussion
- 10:45 am Cervical Spine Dx/Tx
- 1:30 pm Adjourn

### Sunday, January 23, 2000

- 7:00 am Coding for Diagnosis/  
Reimbursement
- 8:00 am Extremities Dx/Tx
- 10:30 am Small Group Discussion
- 10:45 am Complications & Contraindications
- 11:30 am Complete Treatment Approach
- 12:30 pm Summary
- 1:00 pm Adjourn

### Faculty:

Boyd R. Buser, DO, Program Chairperson  
Mark S. Cantieri, DO, FAAO, AAO President

### Suggested Dress:

Loose fitting sports attire, jogging attire, etc.

### REGISTRATION FORM

#### Intro to OMT/HVLA, January 20-23, 2000

Full Name \_\_\_\_\_

First Name for Badge \_\_\_\_\_

Street Address \_\_\_\_\_

City \_\_\_\_\_ State \_\_\_\_\_ Zip \_\_\_\_\_

Daytime phone # \_\_\_\_\_ Fax \_\_\_\_\_

AOA # \_\_\_\_\_ College/Yr Graduated \_\_\_\_\_

I require a vegetarian meal

#### REGISTRATION RATES

BEFORE 12/20/00 AFTER 12/20/00

AAO Member	\$575	\$675
Intern/Resident/Student	\$275	\$375
AAO Non-Member	\$675	\$775

AAO accepts Visa or Mastercard

Credit Card # \_\_\_\_\_

Cardholder's Name \_\_\_\_\_

Date of Expiration \_\_\_\_\_

Signature \_\_\_\_\_



should be thoroughly educated about these techniques. The patient should be instructed on stretches and exercises such as, pelvic tilts, knee pulls, curl ups and straight-leg lifts, which can strengthen the abdominal and lumbar muscles and minimize the pain.<sup>10</sup> The patient should also be instructed on the benefits on minimizing weight gain, which leads to extra lumbar stress, and the benefits of low level aquatic exercise.<sup>6</sup> The patient can also be informed about using a wedge shaped pillow to support the abdomen when lying on her side.

## Discussion

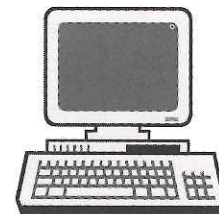
Low back pain is a very common complication of pregnancy. It occurs in over half of pregnant females. Generally, it has been accepted as a normal side-effect of pregnancy. Thus, it is usually left untreated due to the lack of knowledge of simple, conservative, non-invasive techniques that can be used to relieve back pain in the obstetric patient. As osteopathic physicians we are educated in these techniques and have the capabilities to treat these patients and create a better experience for them. However, even with these techniques, the obstetric patient offers a challenge to the physician in diagnosing and treatment of the symptoms. This is because of the limitation of the positions into which the physician can place the patient on the manipulation table. The obstetric patient is basically limited to the lateral recumbent and seated positions, especially in the later weeks of pregnancy. Therefore the physician must alternate these techniques and adapt to the limitations in positions. This becomes especially important because the obstetric patient tends to have a greater amount of somatic dysfunction than just low back pain. It is also common for the

obstetric patient to experience somatic dysfunction in the thoracic and cervical regions, most likely due to compensation from the pelvic instability. The obstetric patient also experiences somatic dysfunction of the coccygeal region, and will experience frequent headaches and disruptions of the basic cranial rhythm.

Osteopathic physicians have been assisting pregnant females with their somatic dysfunctions for many years by altering techniques or designing new techniques, such as the lateral recumbent springing technique illustrated by Treadwell and Magnus in 1996. However, there is a severe lack of publications on these techniques and research a lack of on the effectiveness of the treatments. It is important for osteopathic physicians to attempt to expose the medical community to these techniques and their effectiveness. This exposure will enhance the abilities of physicians to assist obstetric women in the side effects of pregnancy and to develop a more enjoyable experience for the pregnant female.

## References

1. Ashkan, K., A.T.H. Casey, M. Powell and H.A. Crookard. Back pain during pregnancy and after childbirth: an unusual cause not to miss. *J. Royal Soc. Med.*, 91; 88-89; 1998.
2. Daly, J.M., P.S. Frame and P.A. Rapoza. Sacroiliac subluxation: A common, treatable cause of low-back pain in pregnancy. *Fam. Prac. Res. J.*, 11(2); 149-159; 1991.
3. Diakow, P.R.P., T.A. Gadsby, J.B. Gadsby, J.G. Gleddie, D.J. Leprich and A.M. Scales. Back pain during pregnancy and labor. *J Manip. Physio. Ther.*, 14(2); 116-118; 1991.
4. Garmel, S.H., G.A. Guzelian, J.G. D'Alton and M.E. D'Alton. Lumbar disk disease in pregnancy. *Ob. & G.*, 89(5); 821-822; 1997.
5. Guthrie, R.A. and R.H. Martin. Effect of pressure applied to the upper thoracic (placebo) versus lumbar areas (osteopathic manipulative treatment) for inhibition of lumbar myalgia during labor. *JAOA*, 82(4); 2472-51; 1982.
6. Heckman, J.D. Managing musculoskeletal problems in pregnant patients. *J. Musculo. Med.*, 1(7); 14-24; 1984.
7. Hitchcock, M.E. Osteopathic care in pregnancy. *Osteo. Ann.*, 19-29; 1976.
8. McIntyre, I.N. and N.A. Broadhurst. Effective treatment of low back pain in pregnancy. *Aust. Fam. Phys.*, 25(9), suppl.2; S65-S67; 1996.
9. Ostgaard, H.C. Assessment and treatment of low back pain in working pregnant women. *Sem. in Perinat.*, 20(1); 61-69; 1996.
10. Rathmell, J.P., C.M. Visconi and M.A. Ashburn. Management of Nonobstetric pain during pregnancy and lactation. *Anesth Analg.*, 85; 10743- 1087; 1997.
11. Stureson, B., G. Uden, B. Midwifery and A. Uden. Pain pattern in pregnancy and "catching" of the leg in pregnant women with posterior pelvic pain., *Spine*, 22(16); 1880-1884; 1997.
12. Tettambel, M. Structural and hormonal influences on pelvic mechanics in labor and delivery. *AAOJ*, 1721; winter 1995.
13. Treadwell, R.C. and W.W. Magnus. Sacral shear: review and a new treatment method for obstetrical patients. *AAOJ*, 16-18; spring 1996. □



Visit the  
**American Academy  
of Osteopathy's**  
Home on the Internet  
<http://www.aao.medguide.net>



4. Magnetic resonant angiography of the circle of Willis, carotid and vertebral vessels were all normal.

Additional history includes depression with heavy alcohol use and panic attacks, which were treated with a mild anxiolytic. The patient complained of "trailing" vision for several years. His description of this was that when an object passed through his visual field, it was followed by additional overlapping images of the object as if 'trailing' behind the original. Medications: sertraline hydrochloride 50 mg per day, clonazepam .05 mg three times a day, alprazolam .25 three times a day as needed for anxiety

*Structural evaluation on initial exam:*

Standing: The acromion was superior on the right. Iliac crest and trochanteric heights were superior on the right. The forward bending test was negative. Decreased range of motion for the thoracic spine during right side-bending. A mild rotoscoliosis of the high thoracic spine with convexity to the left. The flexion test became positive on the right with arms extended over his head. An obvious tremor of the right arm was noted while in this position.

Seated: The forward bending test was negative and was not changed with arms over his head. There was decreased trunk rotation range of motion to the right. Decreased scapular abduction was noted on the left as well as restricted scapular retraction on the right.

Supine position: The medial malleoli were equal as were the pubic symphysis. Control of pelvic musculature for anterior and posterior tilt as

well as bilateral rotation was normal. Neck flexion was restricted for use of deep flexors and there was substitution by the superficial flexors .

Prone position: No iliac shear or rotation was noted. Hip extension was full and equal using the appropriate musculature without excessive pelvic rotation, nor was there an inordinate amount of use of the upper back musculature for stabilization. Hip abduction was normal and equal bilaterally.

Sensorimotor examination in a standing position was fair. The patient was able to balance on each foot with arms down and eyes open for 30 seconds. However, there was significant foot movement; left foot standing was worse. He was unable to stand on either foot with his arms crossed over his chest and eyes open for five seconds.

Myofascial stress patterns revealed restriction of the occipitoatlantal junction especially involving the splenius capitus and cervicis on the left. This extended to the cervicothoracic junction and included the middle and posterior scalene, as well as the superior trapezius and the levator scapule on the left. On the right cervical spine there was inhibition of the deep flexors extending to the cervicothoracic junction. Also involved were restrictions of the sternocleidomastoid as well as the anterior scalene, both being tight and short.

The middle and lower trapezius and rhomboids were tight and restricted on the right, as well as the middle and upper portions of the thoracic erector spinae group. The latissimus dorsi was tight and restricted on the left. The right scapulothoracic musculature was loose, weak and restricted.

Cranial rhythmic impulse evaluation revealed a normal rate; however the amplitude and vitality were significantly decreased. There was right sphenobasilar torsion, as well as an inferior vertical strain and left side-bending pattern.

An inhalation restriction (first

rib-key rib) of the right upper rib cage was noted. The hamstrings and piriformis were moderately tight and restricted, right greater than left. There was a tight anterior hip capsular pattern on the left as a result of tight, restricted rectus femoris and iliopsoas.

The patient's cervical myofascial restriction were released on the first visit. This was accomplished with an indirect technique involving the muscles and fascia, as well as releasing the most superficial cranial pattern of inferior vertical strain and left side-bending. Generally our patients are not treated on the first visit, so a right temporomastoid suture restriction remained as well as right sphenobasilar torsion.

Second treatment

(eleven days after the initial consultation and first treatment):

He reported a significant improvement in the neck pain, as well as the tremor of the right arm. Both of these had been present for several years according to the patient. Treatment to the right shoulder girdle and latissimus dorsi was accomplished with direct myofascial release, augmented with voluntary muscle firing by the patient. Cervical treatment with muscle energy and myofascial release to the right deep extensors, particularly at the C4, C5, C6 and C7 levels, as well as anterior superficial flexors including stemomastiod, anterior scalene and pectoralis minor.

Third treatment

(eighteen days after first treatment):

The patient stopped drinking alcohol and had only one panic attack, as well as only one dizzy episode. His balance on one foot, alternately, remained unsteady. Myofascial release and indirect functional releases were performed at the sphenobasilar symphysis, atlanto-occipital joint (FRrS left), as well as the right deep exten-

→



sors, particularly C4 through C7 (C2-rotated right), and right superficial flexors. Thoracolumbar junction treatment included the right inferolateral periscapular muscles released with myofascial technique. A sternal indirect functional technique was used to release the anterior chest and scapulothoracic restriction on the right. Exercises and muscle stretches for the patient to do at home were elbow push-ups for serratus anterior, diagonal hip sinks to stretch latissimus dorsi and the shoulder and periscapular regions, pectoralis stretch, and additional bilateral shoulder stretches.

#### Fourth treatment (eleven days after second visit):

One month after the initial visit, the patient had left shoulder pain with tingling in the left hand and some neck pain with dizziness, but no episodes of severe dizziness and nausea and vomiting. There continued to be cranial restriction of the right temporomastoid suture as well as the right torsion. Movement of the temporal bones (which would include the intracranial tentoria) with multiple occipital compressions using the CV4 technique, as described by Upledger,<sup>23</sup> to still-point caused dizziness and nausea. Myofascial release technique as well as indirect functional release was performed by the author and residency director for left shoulder restriction for tight and restricted deltoid, biceps and rotator cuff mechanism. Cervicothoracic junction restriction involving posterior scalene, trapezius and omohyoid was released by author and residency director.

#### Fifth treatment (two weeks after third treatment):

Patient complained of URI symptoms with neck pain and headache, but not as bad as the neck pain had been on the initial visit. The left arm was weak being 4-15 for muscle

strength testing and painful for active range of motion. A significant restriction to the right shoulder mechanism was found and treated with indirect myofascial release. Milder restrictions were found in the cervicothoracic and the thoracolumbar junction myofascial planes. The right cranial torsion had not been released. Thoracic individual vertebral segment dysfunctions at T7 (FRSr) and T8 (ERSr) with ribs 8, 9 and 10 restricted to exhalation were released with muscle energy followed by myofascial technique for the thoracolumbar junction including latissimus dorsi, serratus posterior inferior and erector spinae. Atlanto-occipital and cervicothoracic junctions were treated with myofascial technique.

The patient continued to complain of "trailing" of objects that move across his visual field. Referral to neuro-ophthalmologist resulted in diagnosis of possible neurologic effect of clonazepam. The consulting physician advised the patient to taper dose and stop medication. Additional diagnosis by the neuro-ophthalmologist revealed that the patient's eyes were adducted slightly, bilaterally.

#### Sixth treatment (two weeks after fourth treatment):

Visual trailing persists. Patient still taking clonazepam. Trailing will correct after two to three passes of object, such as patient's hand through the visual field. This was not an improvement from the original manifestation. Patient relates no episodes of severe vertigo with nausea since his initial visit. Headache and neck pain would occur approximately once every two weeks but was seventy five percent less severe than on initial evaluation according to the patient's own admission.

Myofascial restriction of cervical deep extensor muscles on the right was noted including segments C4, C5, C6, C7 as well as posterior scalene and trapezius on the left.

Right scapulothoracic and rotator cuff restrictions were released with muscle energy and myofascial technique. The cranial pattern remained with a right torsion; however the rate and rhythm improvements, as judged by the author, were significant when compared to those seen on initial evaluation.

The patient decided to retire with disability and move to an area distant from the clinic. At this time he will be referred to a Traumatic Brain Injury rehabilitation center near his new home.

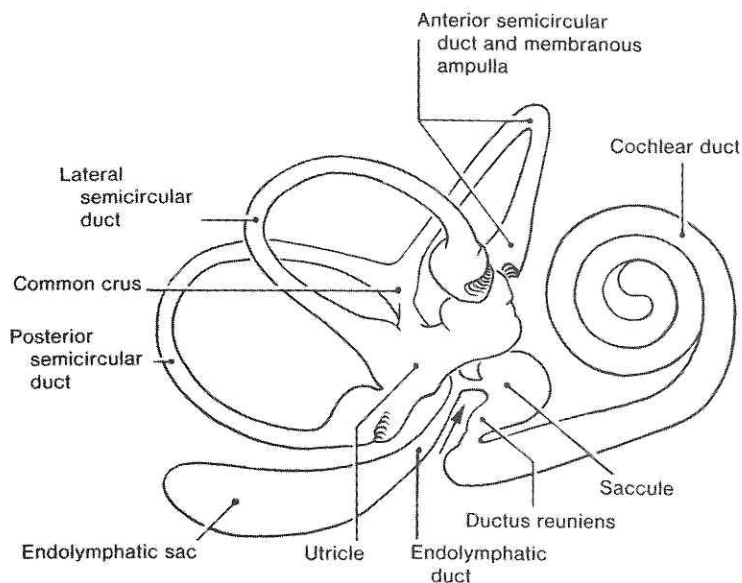
## **Discussion:**

There are very few published, well-documented studies of patients with post-traumatic Meniere's syndrome diagnosed from clinical and temporal bone pathology laboratory evidence in the absence of temporal bone fracture. One such paper was submitted by Paparella and Mancini in 1983.<sup>12</sup> Thirty-seven patients who developed Meniere's syndrome following acoustic (eighteen) and physical (nineteen) trauma were described and discussed. At least 30 percent of 384 patients studied had Meniere's syndrome. Eighteen of these complained of exposure to loud noise either sudden or chronic. Three of 18 patients experienced sudden intense exposure to noise, followed years later by the classic symptom complex. They were all males and the mean age was 52.2 years. Nineteen of 37 patients received physical trauma or blows to the head of which 4 had skull fractures. Of interest in this group, unlike the acoustic trauma group, 7 of 19 patients developed Meniere's syndrome soon (within a month) after trauma. In 3 of 19 cases in which trauma caused sudden hearing loss, Meniere's syndrome fully developed several years later. In the discussion of these case reports Paparella and Mancini made several important observations.

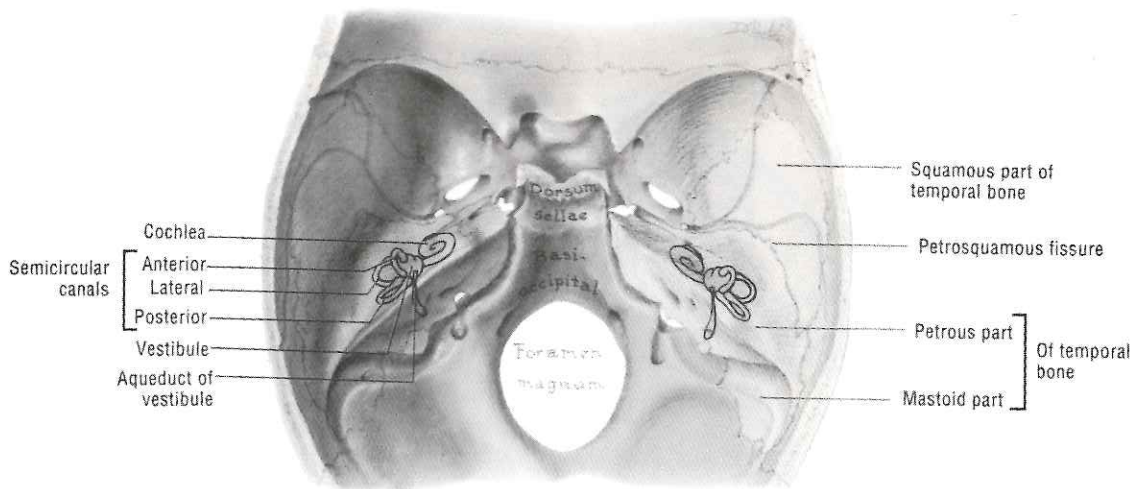
In no case could they be "absolutely" certain that trauma was not coincidental because of the uncertainties of the history-taking process.



**Figure 1.** Lateral view of membranous labyrinth (right side). *Clinically Oriented Anatomy, Moore, Figure 7-124, p 777.*



**Figure 2.** Temporal bone and bony labyrinth. *Clinically Oriented Anatomy, Moore, Figure 7-121, p 772.*



However, using one case in which histopathological information was available as an example, it was difficult for them to exclude the important role of trauma while considering chronological and sequential events. "Disabling or incapacitating attacks of vertigo were the chief complaint in virtually every patient. Positional vertigo was a prominent complaint especially during episodes of

non-positionally incited attacks of vertigo. However, in some patients, especially those with vestibular Meniere's, positional vertigo was a severe problem between typical Meniere's vertigo attacks."

When considering the pathogenesis of trauma causing endolymphatic hydrops associated with Meniere's syndrome, the authors postulated that a shock to the membranous labyrinth

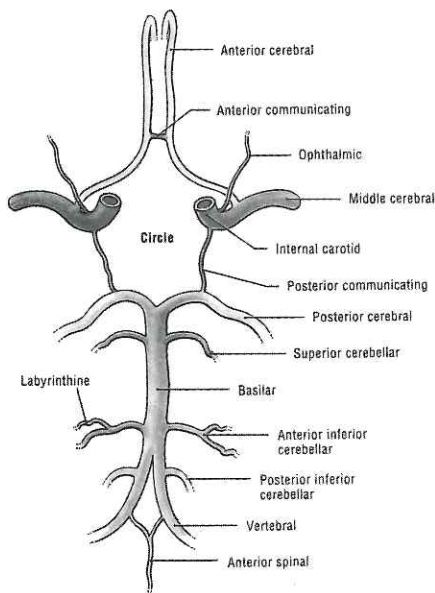
resulted in displaced epithelia of the sensory organs and other cellular elements, which mechanically or chemically caused decreased endolymph absorption by blocking the endolymphatic duct resulting in endolymphatic hydrops and thus, Meniere's syndrome.

Ikeda<sup>9</sup> has demonstrated that there were fewer and smaller blood vessels

→



**Figure 3.** Cerebral arterial circle (of Willis), Figure 7.25, Grants Atlas of Anatomy, p 471.

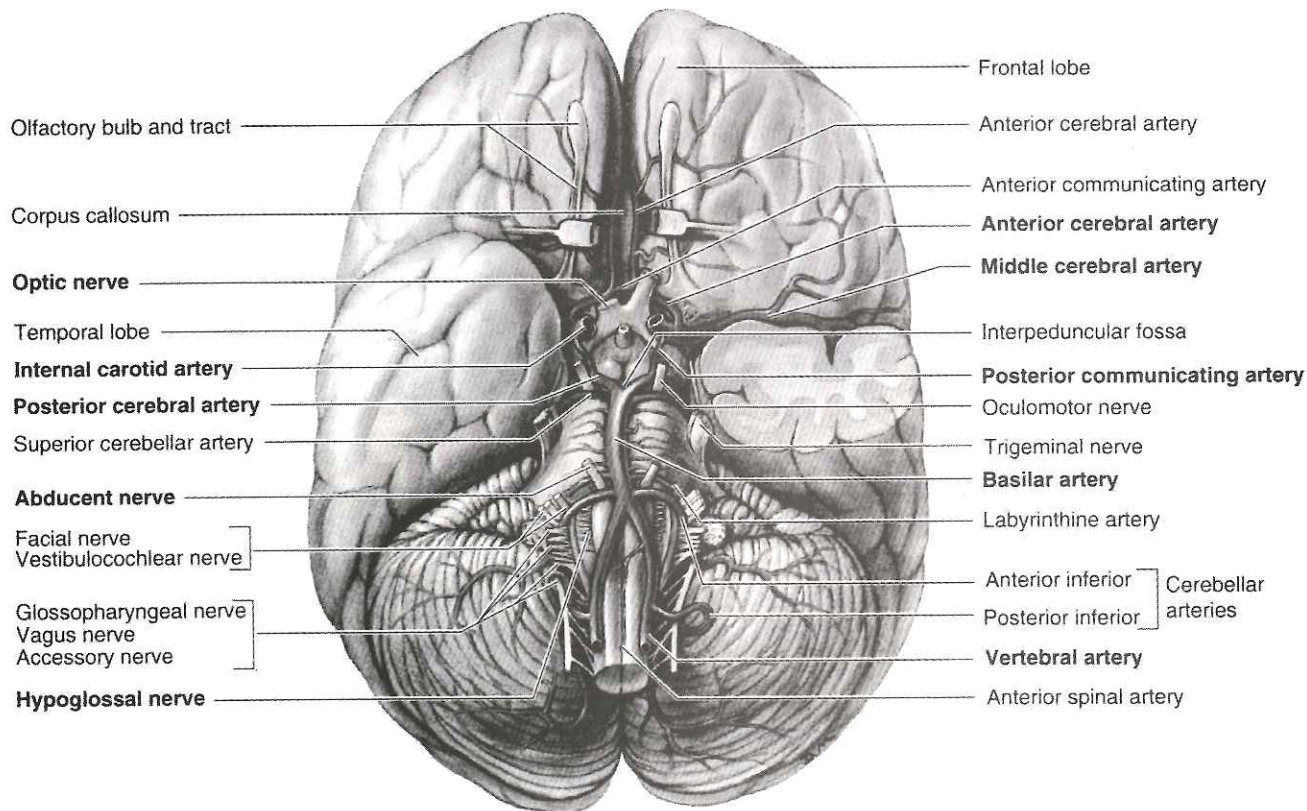


in the endolymphatic sac (ES) of bones from individuals with Meniere's Disease than in the ES's of control bones. This is particularly true in the rugose and the cranial orifice portions of the sac. He describes the meshwork of the loose perisaccular connective tissue surrounding the ES as normally being richly vascular under light microscopic and ultrastructural studies. Diminution of the vascularity of perisaccular connective tissue has been noted by the authors after examination of surgical specimens of the endolymphatic sac from patients with Meniere's Disease. The investigators were able to demonstrate differences between size-matched temporal bones comparing those with a history of Meniere's and those without any clinical history of same. Neither group had any other types of CNS involvement, eighth nerve tumor or other cochleovestibular disease as de-

termined by the results of clinical tests on the living patient. There were fewer vessels in the bones with hydrops, as well as the larger vessels being smaller in size. The differences in vascularity was not related to vestibular aqueduct size in either of the study groups.

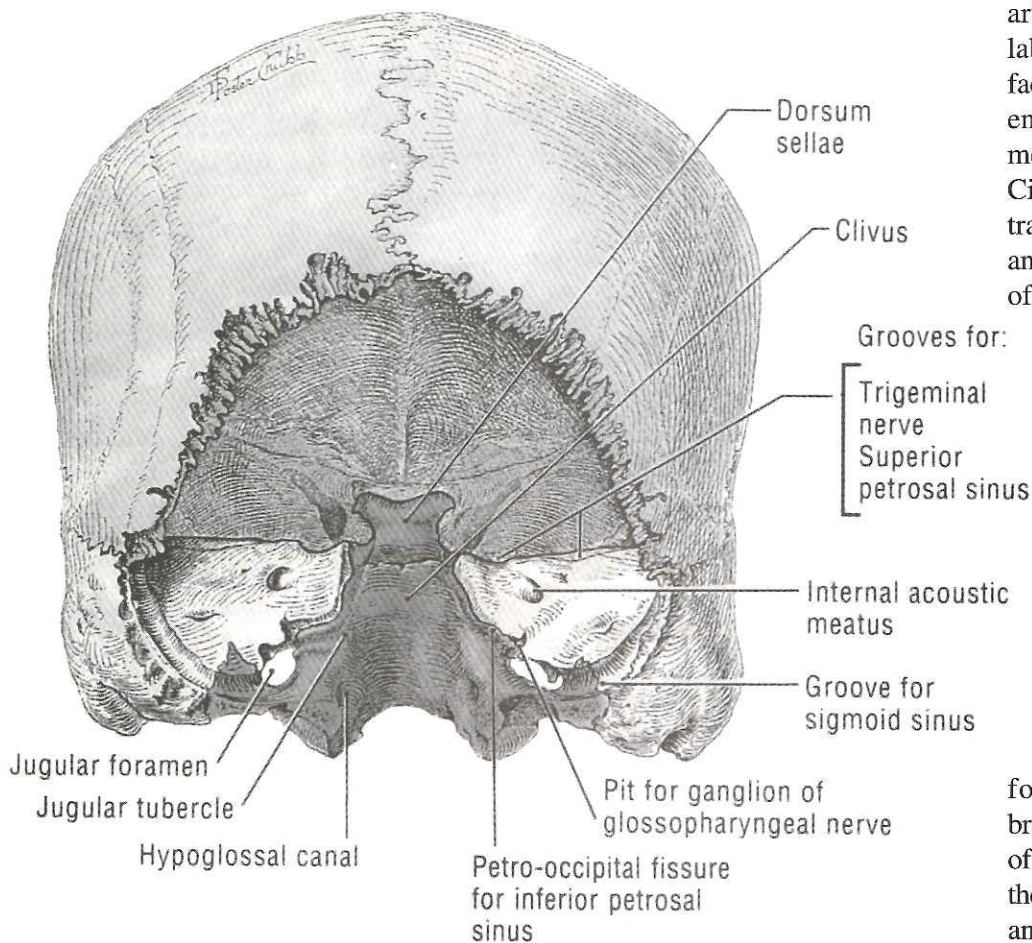
The condition of the perisaccular connective tissue seemed to be related to the vascularity of the endolymphatic sac; the fewer the vessels in the ES the more dense was the connective tissue. However, this was not statistically significant. Still this led the authors to conclude that it would be reasonable to believe that the pathological condition of the vasculature could be important in the etiology of Meniere's Disease. Many other investigators<sup>1,5,10,17,20,27</sup> have pointed out that the perisaccular loose connective tissue undergoes fibrotic change in the temporal bones of patients with Meniere's disease.<sup>9</sup>

**Figure 4.** Base of brain: cerebral arterial circle (of Willis). Figure 7.24 Grants Atlas of Anatomy, p 470.





**Figure 5.** Posterior cranial fossa. Figure 7-156, *Grants Atlas of Anatomy*, p 547.



labyrinthine artery branches off of the anterior inferior cerebellar artery (AICA) from the basilar-vertebral artery system. (See Figure 3) The labyrinthine artery travels with the facial and vestibulocochlear nerves to enter through the internal acoustic meatus. Figure 4 shows the complete Circle of Willis; however, this illustration shows the labyrinthine artery and the ACIA as separate branches off of the basilar artery. In the internal

auditory canal very extensive vessel systems were traced by Hansen.<sup>6,7</sup> Considering the petrous part of the temporal bone, vessels on the surface, as well as into the deeper parts, were found to be perfused by the vertebral artery system. From the AICA sling usually one to three branches supply temporal bone structures via the internal auditory canal and/or the subarcuate

fossa. However, the number of branches vary considerably. The range of small arterial branches detected from the AICA sling were as many as eleven and as few as three. Some branches traveled to nerve sheaths, some to the subarcuate fossa and some through the internal auditory meatus. See Figure 5.

The most proximal of these arteries was usually the largest, the labyrinthine artery. After entering the internal auditory canal it followed the superior anterior side of the acoustic nerve, dividing into several branches. This is where the arteries and nerves that supply the structures of the inner ear pierce the dura mater. See Figure 6.

The dura is contiguous with the thinner neuro-epithelium after it penetrates the openings in the inner table of the cranium. The neuro-epithelium covers the nerves through their courses. It is here that the area of restriction of the artery is most likely. If the dura were compromised in any way such that there was restriction on

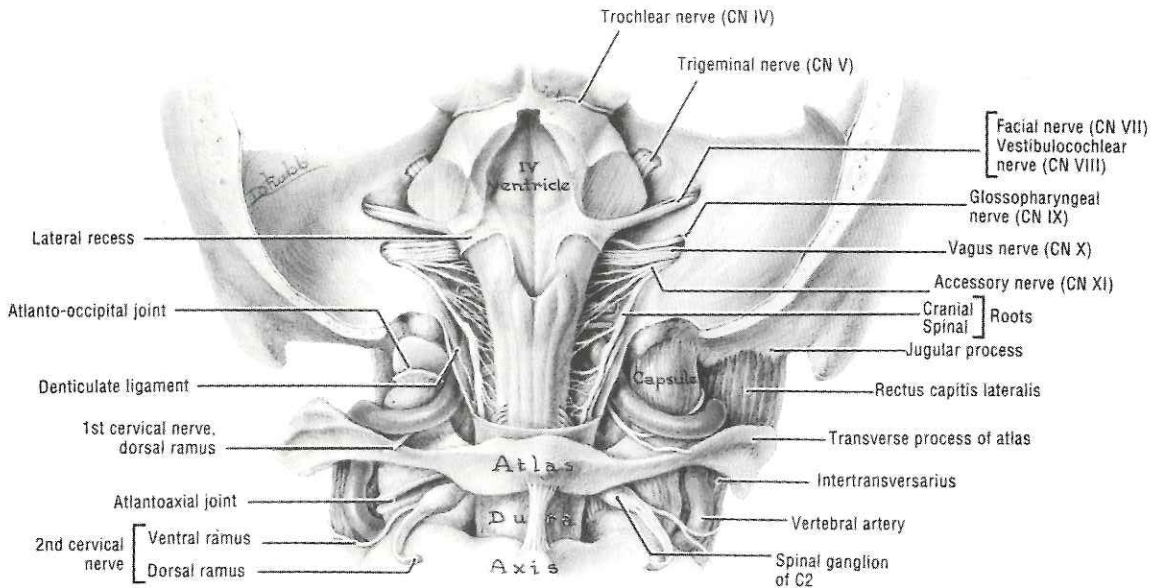
A related paper from Sweden studied a very minute structure within the inner ear.<sup>21</sup> The paravestibular canaliculus (PVC) can regularly be found at microdissection. It runs through the petrous portion of the pyramid (of the temporal bone) from the vestibular portion to the posterior cranial fossa in close proximity to the vestibular aqueduct. It houses mainly veins representing the primary drainage system from the vestibule.<sup>16,18</sup> Besides blood vessels, the canaliculus is filled with loosely textured connective tissue similar to that typical of the vestibular aqueduct (VA). Numerous tiny vascular channels connect the PVC with the VA. Apart from its drainage function, it is postulated that the canaliculus is of nutritional importance for the endolymphatic duct and

the proximal portion of the sac. These investigators found that a very significant portion of the temporal bones of patients with Meniere's disease demonstrated dense, nonpneumatized bone around the VA rather than the loose connective tissue. They concluded that the absence of connective tissue could correspond to the absence or malformation of PVC.

It is reasonable to assume that the loss of connective tissue is due to the loss of vasculature support for the areas surrounding the aforementioned structures. This poses the question of mechanism for the loss of blood and other normal homeostatic mechanisms to an area that would result in what appears to be fibrotic change of these same tissues. A review of anatomy of the area reveals that the



**Figure 6.** Cranial nerves, exposed posteriorly. *Grants Atlas of Anatomy, Figure 7.33, p. 475.*



the structures entering the foramen, the blood vessels would be the most likely to be affected. As a result of injury the venous system would be affected subacutely. The arterial system would be slower to be affected by a chronic restriction, as the venous system would eventually have alternative routes for flow, especially after the edema had subsided. In addition, those specimens with fewer branches from the labyrinthine artery would seem more likely to be affected distally by a restriction in blood flow.

Evidence of regional arterial flow restriction secondary to trauma can be seen by Single-Photon Emission Computed Tomography (SPECT) examination in patients with documented Traumatic Brain Injury (TBI). SPECT has been reported as showing areas of decreased perfusion in the regions of the brain that are linked to TBI patient symptoms, i.e., hearing loss or visual defects.<sup>8</sup> Abnormalities in cerebral hemodynamics have been demonstrated in animals and humans after mild head injury.<sup>4</sup> Change in the epithelium of the endolymphatic sac from columnar to simple cells would indicate a loss of function and a more simplified cellular structure resulting

from a chronic decreased blood flow and alteration of normal homeostasis. Furthermore, the association of the loss or malformation of the paravestibular caniculus with dense surrounding tissue in Meniere's patients could indicate loss of perfusion. It is a well-known clinical fact that decreased perfusion to an area leads to fibrotic change of connective tissue. This is especially true of a chronic restriction which is not corrected by normal mechanisms before fibrotic changes occur.

Note that patient number one had an abnormal auditory brain stem evoked potential in 1995 suggesting a dysfunction between the inner ear and brain stem bilaterally. However, five years previously, auditory and visual evoked potential testing suggested no evidence of dysfunction, although the patient was symptomatic; but he was less so than when he was referred to the Department of Osteopathic Manipulative Medicine. This suggests a progressive nature of change such as that seen with Meniere's disease or syndrome. Concussive injury to the head or specifically to the temporal bone could serve as the source of the restriction that

impedes blood flow and leads to fibrotic change.

## Conclusion:

The two patients presented here have Meniere's syndrome. Etiology of the syndrome can be related to trauma in both cases. The evidence for diagnosis of mild to moderate Traumatic Brain Injury from multiple closed-head injuries is compelling considering the histories of these two patients. The cause and effect mechanism is suggestive of chronic decreased perfusion of the innermost structures of the petrosal portion of the temporal bone and the loose connective tissues surrounding the periaqueductal structures in the inner ear. The loss of proper homeostatic mechanism by blood flow restriction may have led to fibrosis of the connective tissues of the endolymphatic structures with the result of endolymphatic hydrops and thus the symptoms of Meniere's syndrome.

## Additional considerations:

More specific to cranial anatomy is the possibility of stress on the



dura mater where it attaches to the petrous portion of the temporal bone resulting in mechanical stress on the blood vessels.<sup>23</sup> Although patient number one's symptomatology was relatively improved in occurrence and severity, the failure to completely resolve his symptoms suggests that he has fibrosis of the dura mater. The inability of the author as well as a consulting physician to restore the normal cranial rhythmic impulse and symmetry suggests a system resistant to alteration following multiple occasional traumatic head injuries over five decades. Subjective improvement associated with osteopathic manipulative-treatment included less low back pain due to sacral dysfunction and an apparent reduction in the number of episodes of severe vertigo, nausea and vomiting.

Patient number two reported significant changes in headache and neck pain, as well as a subjective reduction in the frequency of episodes of severe vertigo with nausea. There was improvement in the use and function of the right and left arms, pertaining to tremor and weakness. The failure of the magnetic resonant angiography to demonstrate vascular changes and fibrosis is not surprising, since every evaluation was normal and the findings were subtle. The inability to release the persistent right sphenobasilar torsion would once again suggest a system resistant to change, possibly due to fibrosis.

## Recommendations:

This author strongly suggests an aggressive approach to patients with neurosensory loss, including balance problems that can be attributed to traumatic head injury after magnetic resonant imaging with angiography and Single-Photon Emission Computerized Tomography have been utilized. Particular attention should be paid to the brain and connective tissues including the dura mater adja-

cent to the area responsible for sensory nerve processing. A consultation by physicians trained in the diagnosis and management of structural and functional sensory loss secondary to head injury can be helpful when evaluating any patient exhibiting neurosensory and ear-related symptoms after closed head trauma.

## Bibliography:

1. Arenberg I, Morovitz W, Shambaugh G: The Role of the Endolymphatic Sac in the Pathogenesis of Endolymphatic Hydrops in Man. *Acta Otolaryngol (Stockh) Suppl* 1970; 275: 1-49.
2. Arnholt-Schneider M: Degree of Pneumatization of the Temporal Bone and Meniere's Disease: Are They Related? *Am. J. Otolaryngol.* 1990; 11: 33-36.
3. Canalis R, Gussen R, Abemayor E: Endolymphatic Hydrops After Fenestration: A Temporal Bone Study With Implications on the Function of the Utriculo-Endolymphatic Valve. *Am J Otolaryngol.* 1989; 10: 404-409
4. Evans R, The Postconcussion Syndrome and the Sequelae of Mild Head Injury, *Neurologic Clinics.* November 1992; p 815-48.
5. Hallpike C, Cairns H: Observation on the Pathology of Meniere's Syndrome. *J Laryngol Otol* 1938;53: 625-55.
6. Hansen C: Vascular Anatomy of the Human Temporal Bone, a preliminary report: *Acta Otolaryngol. Suppl. (Stockh).* 1973; 309: 1-92.
7. Hansen C: The Aetiology of Perceptive Deafness. *Acta Otolaryngol* 1973; 309: pp90.
8. Ichise M, Dae-Gyun C, Wang P, Wortzman G, Gray B, Franks W: Technetium-99m-HMPAO SPECT, CT and MRI in the Evaluation of Patients with Chronic Traumatic Brain Injury: A Correlation with Neuropsychological Performance. *J Nucl Med* 1994; 35: 217-226
9. Ikeda M, Kando I: Vascularity of Endolymphatic Sac in Meniere's Disease, a histopathological study. *Ann Otol Rhinol Laryngol* 1984; 93: 540-6
10. Ikeda M, Sando I: The Endolymphatic Sac in Patients with Meniere's Disease. A temporal Bone Histopathological Investigation: *Ann Otol Rhinol Laryngol* 1984; 93: 540-6.
11. Kochanek P: Ischemic and Traumatic Brain Injury: Pathobiology and Cellular Mechanisms. *Crit Care Med* 1993; Sep 21 (9 Suppl). p S333-5.
12. Paparella M: The Cause (Multifactorial Inheritance) and Pathogenesis (Endolymphatic Malabsorption) of Meniere's Disease and Its Symptoms (Mechanical and Chemical). *Acta Otolaryngol (Stockh)* 1985; 99: 445-451.
13. Paparella M: Pathogenesis of Meniere's Disease and Meniere's Syndrome: *Acta Otolaryngol (Stockh)* 1984 in press.
14. Paparella M, Mancini F: Trauma and Meniere's Syndrome. *Laryngoscope* 1983;93:1004-1012.
15. Rauch S, Merchant S, Thedinger B: Meniere's Syndrome and Endolymphatic Hydrops, Double Blind Temporal Bone Study. *Ann Otol Rhinol Laryngol* 1989; 98:873-83.
16. Rask-Andersen H: The Vascular Supply of the Endolymphatic Sac. *Acta Otolaryngol (Stockh)* 1979; 88: 315-27.
17. Saito H, Kitahara M, Yazawa Y, Matsumoto M: Histopathologic findings in surgical specimens of endolymphatic sac in Meniere's Disease. *Acta Otolaryngol (Stockh)* 1977;83: 465-9.
18. Sando J, Egami T, Harada T: Course and Contents of the Paravestibular Canaliculus: *Ann Otol Rhinol Laryngol* 1980; 89: 147-156.
19. Sando I, Ikeda M: The Vestibular Aqueduct in Patients with Meniere's Disease, a temporal bone histopathological investigation. *Acta Otolaryngol (Stockh)* 1984; 97: 558-70.
20. Schindler R: The ultrastructure of the endolymphatic sac in Meniere's Disease: *Otorhinolaryngol* 1979; 25: 127-33.
21. Stahle J, Wilbrand H: The Temporal Bone in Patients with Meniere's Disease. *Acta Otolaryngol (Stockh)* 1983; 95: 75-80.
22. Thomsen J, Schroder H, Klinken L, Jorgensen M: Meniere's Disease: Peripheral or Central Origin, a neuro-anatomical study. *Acta Otolaryngol (Stockh) Suppl* 1984; 406:46-51.
23. Upledger J, Vredevoogd J: *Craniosacral Therapy.* Eastland Press, Seattle; 1983.
24. Wadin K: Radioanatomy of the High Jugular Fossa and the Labyrinthine Portion of the Facial Canal.
25. Yamakawa K: Uber die pathologische Veranderung bei einem Meniere-Kranken. *J Otorhinolaryngol Soc(Jpn)* 1938;44: 2310-2.
26. Yazawa Y, Kitahara M: Bilateral Endolymphatic Hydrops in Meniere's Disease: Review of Temporal Bone Autopsies. *Ann Otol Rhinol Laryngol* 1990; 99: 524-28.
27. Zechner G, Altmann F: Histological Studies on the Human Endolymphatic Duct and Sac. *Pract OtoRhinoLaryngol* 1969; 31: 65-83.
28. Atkinson M: Meniere's original papers. Reprinted with an English translation together with commentaries and biographical sketch. *Acta Otolaryngol [Suppl (Stockh)]* 1961(suppl 162). □





3500 DePauw Boulevard, Suite 1080  
Indianapolis, IN 46268-1136

ADDRESS CORRECTION AND  
FORWARDING REQUESTED

NON-PROFIT ORG.  
U.S. POSTAGE  
PAID  
PERMIT #14  
CARMEL, INDIANA

*DISNEY, OMT, AND YOU AT THE . . .*

# NINTH ANNUAL OMT UPDATE

*(INTERMEDIATE COURSE)*

*“APPLICATION OF OSTEOPATHIC CONCEPTS IN CLINICAL MEDICINE”*

PLUS PREPARATION FOR CERTIFYING BOARDS

**SEPTEMBER 22-25, 1999**

This Academy program was designed to meet the needs of the physician desiring the following:

- OMT Review - “hands-on experience and troubleshooting”
- Integration of OMT in treatment of various cases
- Preparation for OMM practical portions of certifying boards
- Preparation for AOBNM (American Osteopathic Board of Neuromusculoskeletal Medicine) certifying board
- Information on CODING for manipulative procedures
- Good review with relaxation and family time

**LOCATION:** The Contemporary Hotel (Walt Disney World® Resorts) Lake Buena Vista, FL

**CME HOURS:** 4 days; 22 hours; AOA Category 1-A

**CONTACT : AMERICAN ACADEMY OF OSTEOPATHY FOR MORE INFORMATION:**

**3500 DEPAUW BLVD., SUITE 1080, INDIANAPOLIS, IN 46268-1136**

**PHONE: (317) 879-1881; FAX: (317) 879-0563; OR E-MAIL: AAODLF@AOL.COM**